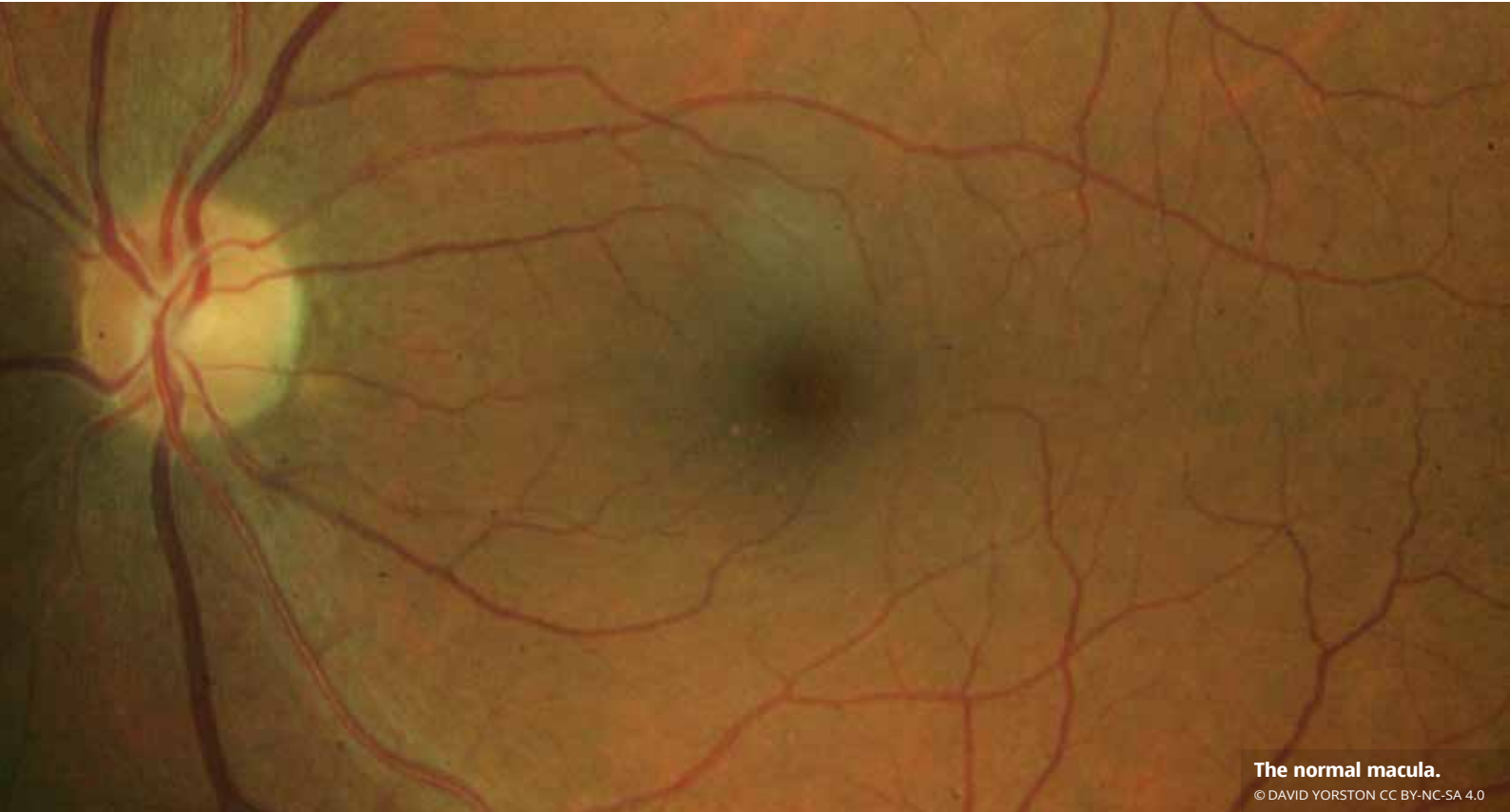


Don't miss out

Download the free  
Community Eye Health  
Journal app today!  
[bit.ly/CEHJ-app](https://bit.ly/CEHJ-app)



SCAN ME



The normal macula.

© DAVID YORSTON CC BY-NC-SA 4.0

## Maculopathies made simple

Macular diseases are on the increase worldwide.



**David Yorston**  
Consultant  
Ophthalmologist,  
Tennent Institute of  
Ophthalmology,  
Gartnavel Hospital,  
Glasgow, Scotland.

The macula is the region of the retina with the highest density of photoreceptors and is responsible for our central vision. Whenever we read print, recognise a face, or examine a patient's eye, we are using our macula. Damage to the macula makes everyday tasks, such as reading and recognising faces, much more difficult.

In this issue of the *Community Eye Health Journal*, we are focusing on the most common and treatable conditions affecting the macula:

- Diabetic macular oedema
- Age-related macular disease
- Surgical maculopathies: epiretinal membrane and macular hole
- Myopic maculopathy.

### Why this issue, why now?

Macular diseases are on the increase worldwide. Diabetes is increasing more rapidly in low- and middle-

income countries compared to high-income countries<sup>1</sup> along with its complications, including diabetic macular oedema. Age-related macular degeneration (AMD) – as its name suggests – tends to affect older people. With more people living to an older age, the number of people with AMD is projected to grow from 195 million in 2020 to over 288 million by 2040.<sup>2</sup> It was the 3rd most common cause of moderate to severe visual impairment worldwide in 2015, after cataract and refractive error, and the 4th most common cause of blindness globally.<sup>3</sup> Myopia is also increasing rapidly worldwide and, with it, complications such as myopic maculopathy.<sup>4</sup>

Macular diseases – particularly exudative macular degeneration and diabetic maculopathy – respond well to intravitreal injections of anti-VEGF drugs, such as bevacizumab. Anti-VEGF drugs are still expensive, but the recent World Health Organization Package of Eye Care Interventions (PECI) specifically includes recommendations for the use of anti-VEGF drugs,



## About this issue

Macular diseases are on the increase worldwide, thanks to the rapid rise in diabetes, ageing populations, and the increasing number of people with myopia, all of which lead to a greater number of people being affected by diabetic macular oedema, age-related macular degeneration, and myopic maculopathy, respectively. These conditions are all treatable, especially if patients are identified and referred appropriately.

## Contents

- 1 Maculopathies made simple**  
David Yorston
- 4 Clinical examination of the macula**  
Andrew Blaikie
- 7 Age-related macular degeneration (AMD): an introduction**  
David Yorston
- 9 Diabetic macular oedema (DMO): an introduction**  
Rajiv Raman and Raja Narayanan
- 11 Anti-VEGF treatment for macular conditions**  
Michael Mikhail
- 12 Surgical maculopathies: epiretinal membranes and full-thickness macular holes**  
Anthony Hall
- 15 Optical coherence tomography: an introduction**  
David Yorston
- 17 Management of myopic traction maculopathy**  
Barbara Parolini
- 20 Biosimilars for anti-VEGF treatment of macular diseases: country and region reports**  
Miriam Cano, Mangala Dhanapala, Mengtian Kang, Mapa Prabhath Piyasena, Rajiv Raman and David Yorston
- 21 Working with patients affected by macular eye conditions**  
Raja Narayanan
- 22 Availability and affordability of anti-VEGF biosimilars in Sri Lanka**  
Mapa Prabhath Piyasena and Mangala Dhanapala
- 24 Key community Eye health messages**

which should make it easier to advocate for their inclusion in national eye health programmes and insurance coverage. Surgical maculopathies, such as macular hole and epiretinal membrane, can be treated using vitrectomy, and the outcomes are good. Patients with myopic maculopathy can benefit from anti-VEGF injections for macular new vessels; traction maculopathy can be improved using a scleral buckle.

### When to suspect a macular condition

The macula is responsible for the detailed vision that is assessed when we measure visual acuity. If the macula has a significant disorder, the visual acuity in that eye will be reduced. If the visual acuity is 6/12 or better, the patient may have a mild problem – early atrophic AMD, or a small epiretinal membrane – but it certainly doesn't need treatment or referral.

If the vision is less than 6/12, the patient may have macular disease, but cataract and refractive error are more common, so look for those first. The patient may also have glaucoma or another condition affecting the optic nerve. If there is no evidence of such conditions, then you can suspect a macular problem (Figure 1).

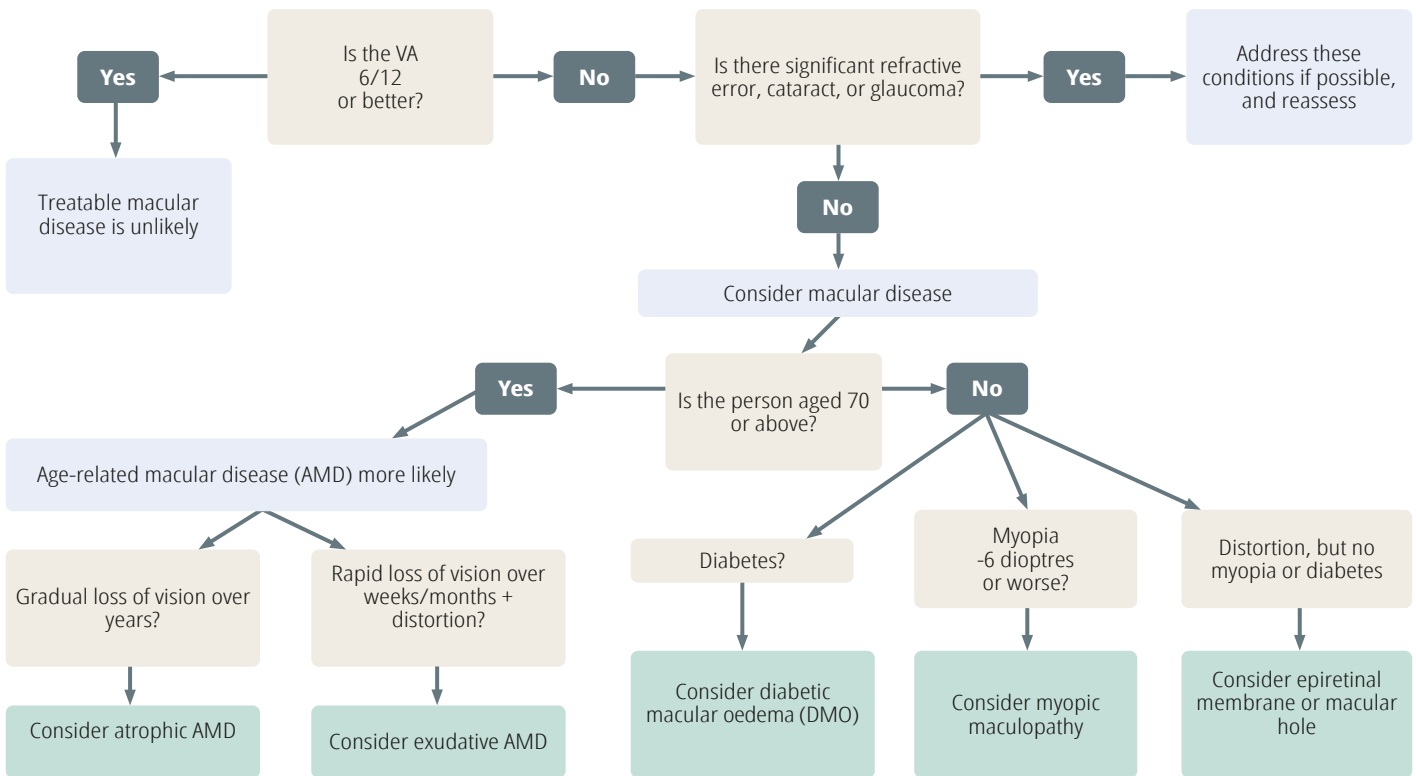
One very helpful pointer to macular disease is distortion, or metamorphopsia. If a patient complains that straight lines look bent, or distorted, it is almost certain that they have a macular problem. Not all macular conditions cause distortion – it is uncommon in atrophic AMD – so the absence of symptoms of distortion does not exclude macular disease. Patients rarely volunteer symptoms of distortion, so, if you suspect a macular disorder, ask the patient to look at a straight line, such as a doorway or window frame, and to report any distortion.

### What macular diseases should I be able to recognise?

The flow diagram in Figure 1 will get you started. This is just a pointer to what is the most likely diagnosis. People with diabetes can get AMD, and macular holes. People with high myopia can have diabetic maculopathy or AMD. However, if someone has no history of diabetes, and normal blood sugar, it is extremely unlikely that they have diabetic maculopathy. If someone has a refractive error of -1.5, it is extremely unlikely that they have myopic maculopathy. If there is no distortion,



**Figure 1** Flow diagram for identifying macular conditions.



they don't have a macular hole. People over 60 can get AMD, but it is much more common in people over the age of 70.

Once you have narrowed down the likely diagnoses, you need to examine the macula. You must dilate the pupil in order to do so. If an eye has severe visual impairment (6/60 or worse) the abnormality of the macula is usually obvious. If there is only mild visual impairment, the signs can be more difficult to detect, but it is almost always possible to identify an abnormal macula (see page 4). These patients should be referred, ideally to a centre able to provide OCT examination (see page 15).

Most patients with macular conditions will still have some visual impairment. It is therefore important to support them to make the best use of their vision, by providing advice and referring them to low vision and rehabilitation support, where available. Patients may benefit from training in eccentric viewing (using peripheral vision).

The Macular Society offers free online training for patients: [www.macularsociety.org/support/daily-life/skills-seeing/evtraining/](http://www.macularsociety.org/support/daily-life/skills-seeing/evtraining/)

**References**

- 1 NCD Risk Factor Collaboration (NCD-RisC). Worldwide trends in diabetes since 1980: a pooled analysis of 751 population-based studies with 4.4 million participants [published correction appears in Lancet. 2017;389(10068):e2. doi: 10.1016/S0140-6736(16)32060-8]. Lancet. 2016;387(10027):1513-1530. doi:10.1016/S0140-6736(16)00618-8.
- 2 Wong WL, Su X, Li X, et al. Global prevalence of age-related macular degeneration and disease burden projection for 2020 and 2040: a systematic review and meta-analysis. Lancet Glob Health. 2014;2(2):e106-e116. doi:10.1016/S2214-109X(13)70145-
- 3 Jonas JB, Cheung CMG, Panda-Jonas S. Updates on the Epidemiology of Age-Related Macular Degeneration. Asia Pac J Ophthalmol (Phila). 2017;6(6):493-497. doi:10.22608/APO.2017251
- 4 Sankaridurg P, Tran H, Tahhan N, Stern J. What can we do about myopia? An evidence-informed approach. Community Eye Health. 2024;37(122):8-9.

**Subscribe**

Visit <https://bit.ly/3uwMvf5>

**Address for subscriptions**

Community Eye Health Journal South Asia Edition, Pragyaan Sustainable Health Outcomes (PRASHO), Floor 2, Kapil Kavuri Hub, no. 144 Survey 37, Financial District, Nanakramguda, Telangana 500032. Email [editor@cehjsouthasia.org](mailto:editor@cehjsouthasia.org)

**Correspondence articles**

We accept submissions of 800 words about readers' experiences in eye health. Contact: [editor@cehjsouthasia.org](mailto:editor@cehjsouthasia.org)

Published by the International Centre for Eye Health, London School of Hygiene & Tropical Medicine.

Unless otherwise stated, authors share copyright for articles with the Community Eye Health Journal. Illustrators and photographers retain copyright for images published in the journal.

Unless otherwise stated, journal content is licensed under a Creative Commons Attribution-NonCommercial (CC BY-NC) license which permits unrestricted use, distribution, and reproduction in any medium for non-commercial purposes, provided that the copyright holders are acknowledged.

ISSN 0953-6833

**Disclaimer**

Signed articles are the responsibility of the named authors alone and do not necessarily reflect the views of the London School of Hygiene & Tropical Medicine (the School). Although every effort is made to ensure accuracy, the School does not warrant that the information contained in this publication is complete and correct and shall not be liable for any damages incurred as a result of its use.

The mention of specific companies or of certain manufacturers' products does not imply that they are endorsed or recommended by the School in preference to others of a similar nature that are not mentioned. The School does not endorse or recommend products or services for which you may view advertisements in this Journal.

The Community Eye Health Journal is supported by:



South Asia Edition supported by:







**Andrew Blaikie**  
 Consultant Ophthalmologist:  
 NHS Fife, St Andrews,  
 Scotland; Senior Lecturer  
 University of St Andrews,  
 St Andrews, Scotland;  
 Honorary Associate Professor:  
 LSHTM, International Centre  
 for Eye Health, London, UK.

# Clinical examination of the macula

The macula needs to be assessed in any patient presenting with loss of vision, particularly if there is a history of visual distortion.

There are three commonly used 'hands-on' tools that can be used to examine the macula: the direct ophthalmoscope, slit lamp, and binocular indirect ophthalmoscope. Each of these have different strengths and weaknesses, and provide different fields of view. As with any practical skill, the best results will be achieved with regular practice and mentorship.

## Before you start

There are a number of assessment steps, before looking at the macula, that will help work out what is wrong with the patient. These steps are common to whatever tool is being used.

### Visual acuity

Assess near and distance acuity, including with a pinhole, to exclude refractive error and presbyopia.

### Distortion

This can be detected using an Amsler chart – a 10cm by 10cm square grid of 5mm squares with a fixation spot in the centre. Disturbance in the appearance of the grid can suggest macular disease. However, looking at any object with straight lines, such as a window frame or doorway, is an effective means of detecting distorted vision.

### Pupils

Perform the direct and swinging pupillary light tests to look for an afferent and relative afferent pupillary defect (RAPD), respectively. An afferent defect is present when the pupil either fails to constrict or does not constrict as briskly as expected on direct illumination. A relative afferent pupillary defect is present when, during the swinging light test, the pupil is seen to paradoxically dilate on illumination. If this sign is present, then the patient is likely to have asymmetrical optic nerve disease or a significant widespread retinal disorder, such as retinal detachment or a vascular occlusion. An afferent or RAPD is considered uncommon in a purely macular condition, although it can occur. Read more at [www.cehjournal.org/articles/412](http://www.cehjournal.org/articles/412)

**Videos**  
 For a playlist of videos about examining the macula, visit [tinyurl.com/bd3e92t](http://tinyurl.com/bd3e92t)



Examining the macula monocularly and indirectly using a direct ophthalmoscope and condensing lens. UK

## Tips for finding the macula

- Examine the patient in a dim room.
- Dilate the pupils. Even very experienced eye care practitioners will struggle to examine the macula through an undilated pupil. This is because the pupil will constrict as soon as light falls on the macula, limiting your view.
- Start with a low light and gradually increase the brightness, so that you can balance the comfort of the patient with your ability to see the detail of the macula.
- In general, to find the macula, first find the optic nerve. Note its contour, colour, and cup. Look temporally, or ask the patient to look at the light. This should bring the macula into view. If not dilated, the pupil will constrict and the view will be lost.
- The macula typically appears slightly darker than the surrounding retina, with a central bright foveal reflex.

## Using a direct ophthalmoscope

When examining the macula, it can be best to start with the patient and the examiner wearing their usual distance refractive correction with the ophthalmoscope set to zero.

Use your right eye to examine the patient's right eye (and your left eye to examine the patient's left eye).


Position your eye at the same horizontal level as that of the patient (Figure 1) and ask the patient to look at a point straight in front of them.

Stand with your feet close to the patient. Lean back and 15 degrees to the temporal side (Figure 2), until you can see the fundal 'red' reflex in both eyes to assess the clarity of the media.

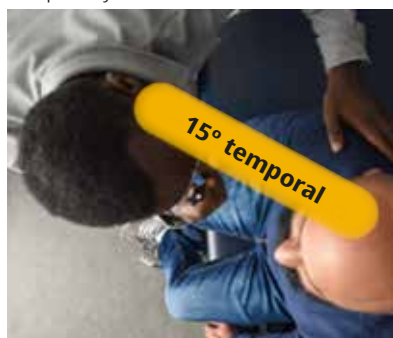From there, slowly lean towards the patient, following the fundal reflex on this horizontal 15-degree temporal 'flight path' to find the optic disc (Figure 3). At first it will appear a bit blurred, but as you get closer it should become clearer. Use the lenses in the ophthalmoscope if it remains blurred.

If you can't find the optic disc, find where the blood vessels join. The natural V shape created where they join is like an arrow pointing towards the disc. Move in this direction to find the disc (Figure 4).

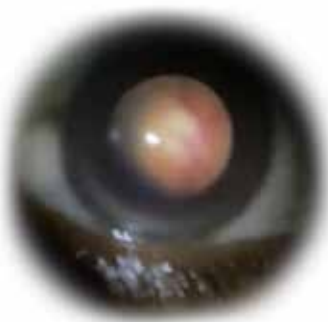**Figure 1** Position yourself so your eye is the same horizontal level as the patient's.



**Figure 2** Lean back and 15 degrees temporally to see the fundal reflex.



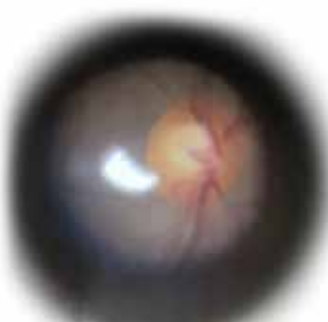**Figure 3** The optic disc.



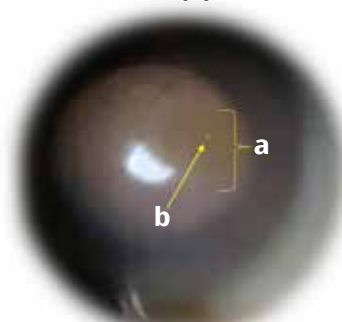
**Figure 4** The V shape created where the blood vessels join (see yellow arrow) is like an arrow pointing towards the optic disc.



**Figure 5** A closer view of the optic disc.



**Figure 6** The macula is the darker area (a). Notice the small bright area in the centre – this is the foveal reflex (b).



Once you locate the optic disc, move closer to the patient get a clearer view (Figure 5). Comment on the contour, colour, and cup of the optic disc.

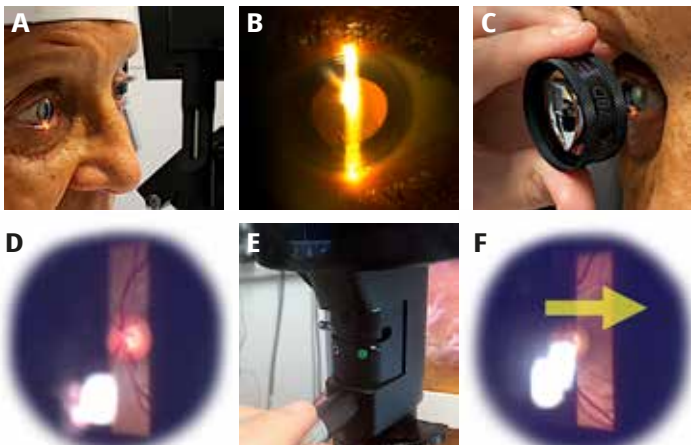
From the optic disc, move temporally until you can see the darker macula and bright foveal reflex (Figure 6).

### Using a slit lamp

Position the patient so that their eyes are at the same level as the black mark on the vertical bar and their head is forward, leaning against the forehead strap (Figure 7A).

Line up the light source and eye pieces to create axial illumination (Figure 7B). Use your fingers to brace the position of the lens

**Figure 7. A:** Forehead against the bar. **B:** Axial illumination; check the reflex. **C:** Brace the lens and hold the upper lid. **D:** Find the disc. **E:** Adjust the light and lens position to optimise the view. **F:** Move temporally to find the macula and fovea, remembering that what is seen is reversed horizontally and vertically.



and hold the eyelid up to reduce blinking. Ask the patient to look slightly temporally, towards your ear.

The optic disc should come into view. Adjust the tilt/distance of your lens and the beam brightness, width, and height to optimise the view. Then move temporally to find macula (Figure 7).

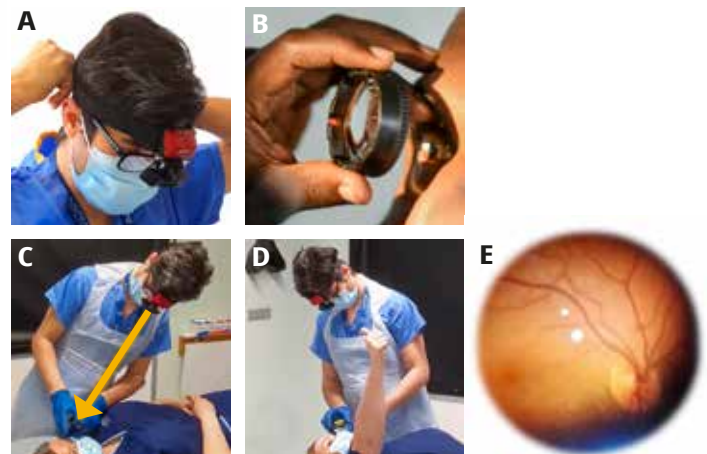
### Using a binocular indirect ophthalmoscope

Patients are best examined lying down, but sitting is okay. Make sure the binocular indirect ophthalmoscope feels comfortable and it is aligned with your eyes so you can see your thumb in the centre of each eyepiece with your arm straight out in front of you.


Use your fingers to brace the lens at the correct distance and hold the patient's upper eyelid open. Ask the patient to look at their thumb. Move the position of their thumb to move their gaze; this will allow you to examine of all parts of the fundus. Tilting the lens and varying the brightness of the light can improve the view (Figure 8).

Indirect ophthalmoscopy can also be performed using the light source of a direct ophthalmoscope. Placing it by the side of the eye allows a monocular view, and between the eyes a binocular indirect view. This is most effective through a dilated pupil, and presbyopic examiners will need to wear near correction (Figure 9).

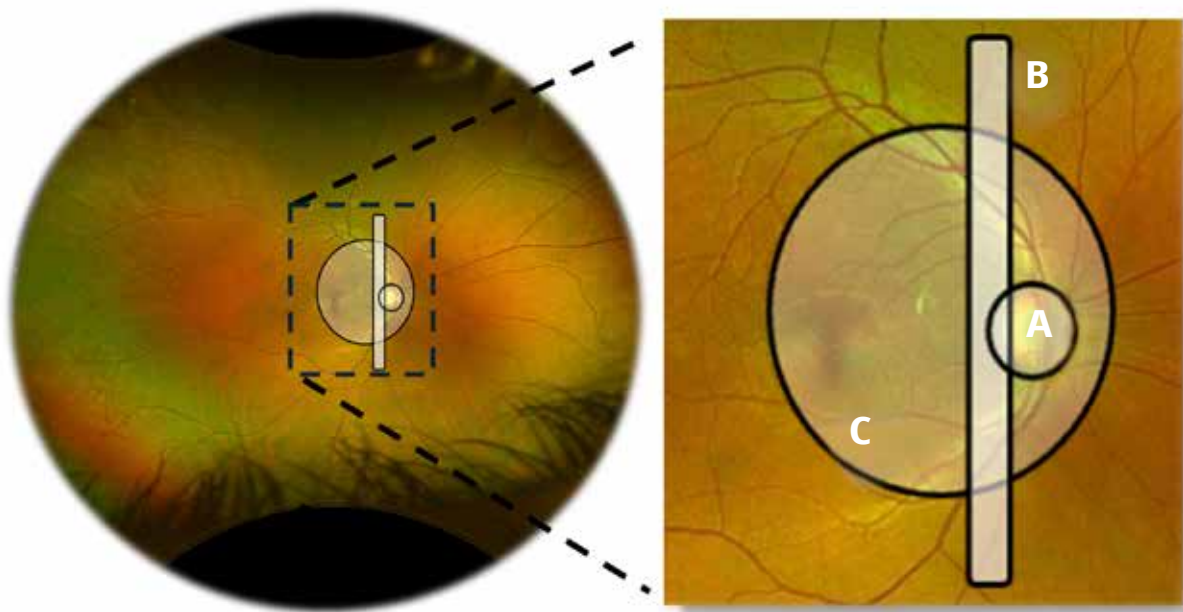
**Figure 8. A:** Ensure the binocular indirect ophthalmoscope fits comfortably. **B:** Use your fingers to brace the lens and hold the upper eyelid. **C:** Line up the eye, lens, and ophthalmoscope as you check the reflex. **D:** Use the patient's thumb as a target. **E:** Typical view of the disc and macula.



**Figure 9** Indirect ophthalmoscopy using the direct ophthalmoscope as a light source. **A:** Monocular view if held to the side **B:** Binocular view is possible if an Arclight is held between the eyes and both eyes are used to view the fundus.



**Figure 10** Relative size of fields of view superimposed upon a widefield Optomap **A:** Direct ophthalmoscope, **B:** Slit lamp, **C:** Binocular indirect ophthalmoscope.



## Which tool is the best?

Different devices and lenses have different optical properties. In general, the greater the magnification, the smaller the field of view (Table 1). For instance, a direct ophthalmoscope has a high magnification, but a very small, monocular field of view. In Figure 10, this is represented by the circle labelled A. Both the slit lamp (B) and the binocular indirect ophthalmoscope (C) offer less magnification but wider, stereo fields of view.

The different devices also have a range of different features and functionality (Table 2). The slit lamp offers excellent anterior segment examination but is the least portable and

most expensive. The binocular indirect ophthalmoscope is typically the best at offering a useful view through hazy media. Both the slit lamp and indirect ophthalmoscope require additional condensing lenses; because of this, the direct ophthalmoscope is often considered the easiest to use.

The preferred technique for examining the macula is the slit lamp, with a 78D lens. However, all the methods are effective, and your choice will depend on several factors.

As with any practical skill, the best results will be achieved with regular practice and mentorship. For instance, someone who most frequently uses a direct ophthalmoscope will be able to detect disease more accurately than someone who only occasionally uses a slit lamp.

**Table 1** Magnification and field of view provided by different tools and lenses. Note: Slit lamp magnifications shown are for a slit lamp at 10x magnification; however, this can be adjusted from 6x to 40x.

Device	Condensing lens power	Magnification	Field of view (degrees)
Direct Ophthalmoscope	N/A	15x	10-15
Slit lamp	60D	11.5x	68-81
	66D	10x	80-96
	78D	9.3x	81-97
	90D	7.6x	74-89
Indirect ophthalmoscope	20D	3x	45-50
	28D	2x	53-58
	30D	1.9x	60-65

**Table 2** Relative strengths and weaknesses of the direct ophthalmoscope, slit lamp and indirect ophthalmoscope.

	Direct ophthalmoscope	Slit lamp	Indirect ophthalmoscope
Portable	+++	-	++
Cost	\$	\$\$\$	\$\$
Magnification	+++	++	-
Field of view	+	++	+++
Binocularity (3D view)	-	+++	+
Ease of use	++	+	+
Can see through cataract	+	++	+++





**David Yorston**  
 Consultant  
 Ophthalmologist,  
 Tennent  
 Institute of  
 Ophthalmology,  
 Gartnavel  
 Hospital, Glasgow,  
 Scotland.

# Age-related macular degeneration (AMD): an introduction

AMD is a progressive disease of the macula, causing loss of central vision, and is more prevalent in older people.

Worldwide, age-related macular degeneration (AMD) causes more visual impairment than any other condition other than refractive error and cataract. An analysis of prevalence studies suggests that there were 196 million people with AMD in 2020; this will increase to 288 million by 2040.

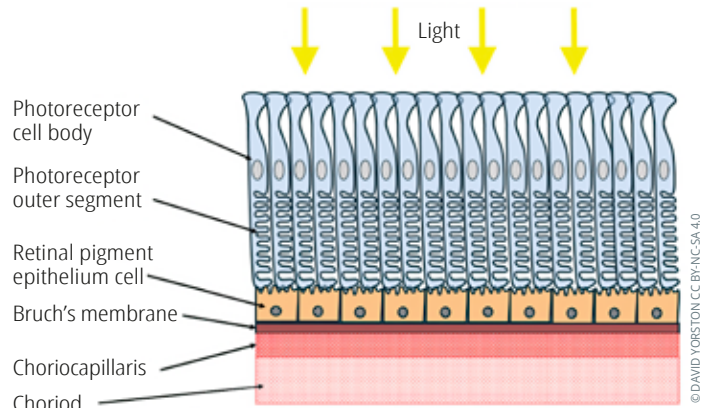
The reason for this increase is demographic change: as the proportion of the population aged over 65 increases, so will the prevalence of AMD, as it is a degenerative process and is more prevalent in older people.

AMD affects the **outer retinal complex** at the macula, consisting of the photoreceptors (also known as the rods and cones), the retinal pigment epithelium (RPE), Bruch's membrane, the choriocapillaris, and the choroid (Figure 1). Damage to one component of this complex rapidly affects all the other components. Once the photoreceptors at the macula are destroyed, central vision is lost.

In a healthy macula, the outer segments of the photoreceptors are continually being renewed. The oldest parts of the photoreceptor outer segments are broken down by the RPE and removed by the circulation in the choriocapillaris. As we age, this process becomes less efficient, and the half-digested remains of the photoreceptor outer segments build up in Bruch's membrane – the layer between the choriocapillaris and the retinal pigment epithelium. This is visible as small, pale sub-retinal spots, called drusen (Figure 2).

A combination of chronic inflammation and reduced circulation in the choriocapillaris then leads to damage to the outer retinal complex, causing loss of vision. This can take the form of atrophy of the RPE and photoreceptors (atrophic or 'dry' AMD), or the development of abnormal new vessels under the retina (neovascular/exudative or 'wet' AMD). These two types often co-exist in the same patient, but it is clinically useful to distinguish between them.

**Atrophic ('dry') AMD** (Figure 4) is due to atrophy of the retinal pigment epithelium, which leads to loss of the



**Figure 1: Normal macula.** Cross-section of the outer retinal complex, showing the photoreceptors (cell body and outer segment), retinal pigment epithelium (RPE), Bruch's membrane, choriocapillaris, and choroid.

photoreceptors. Loss of vision is usually slow and gradual, and is irreversible. When it affects the fovea, there will be severe visual impairment.

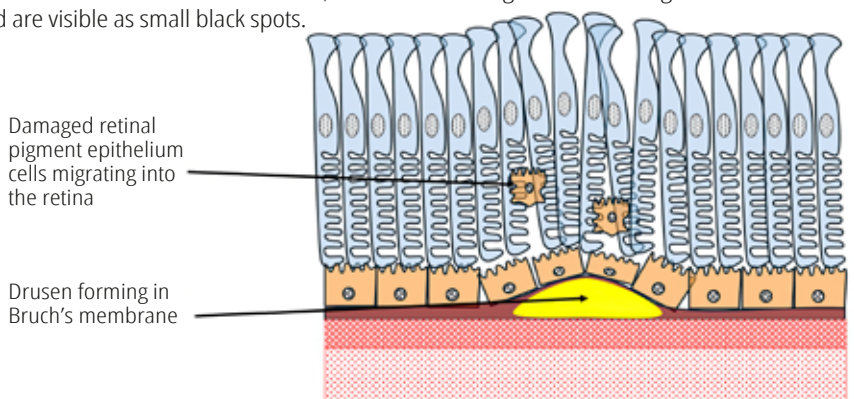
**Neovascular ('wet' or exudative) AMD** (Figure 6) is the result of new, abnormal blood vessels growing under the RPE. These leak fluid into or under the retina, causing swelling (oedema). In the initial stages, vision may be distorted (metamorphopsia) because the oedema results in misalignment of the photoreceptors. Chronic leakage leads to exudates, and sometimes these new vessels rupture, leading to bleeding under the RPE or under the photoreceptor cells (sub-retinal bleeding). Loss of vision is usually more rapid, occurring over days or weeks, but can happen suddenly, particularly if there is sub-retinal bleeding.

## What causes AMD?

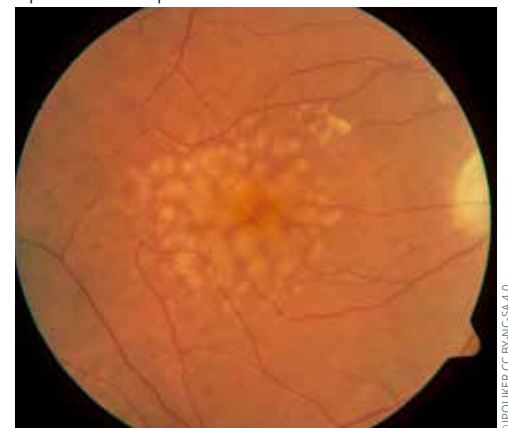We know that certain **genetic abnormalities** increase the risk of developing AMD, particularly mutation in the gene for complement factor H, a protein involved in the regulation of inflammation. If complement H does not function normally, it is thought that inflammation caused by the inefficient removal of photoreceptor outer segments is worse; this leads to damage to the surrounding cells.

We also know that **cigarette smoking** greatly increases the risk of AMD. Tobacco smoke contains chemicals that promote inflammatory responses and increase the risk that early AMD will progress.

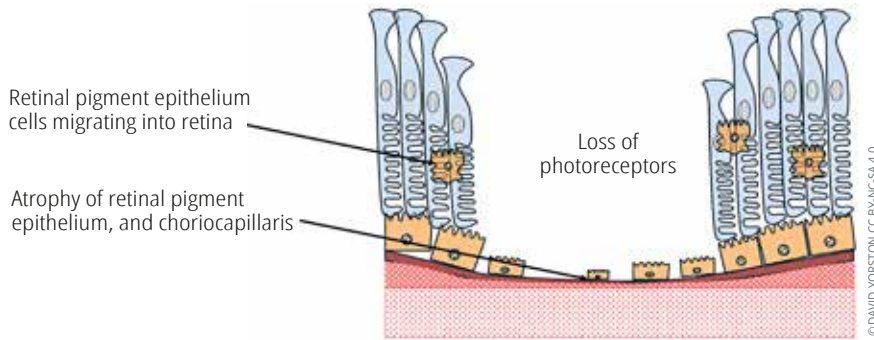
**Figure 2: Early AMD.** The retinal pigment epithelium (RPE) can no longer completely break down the older parts of the photoreceptor outer segments. The remains build up in the thickened Bruch's membrane, as drusen. Damaged RPE cells migrate into the retina and are visible as small black spots.



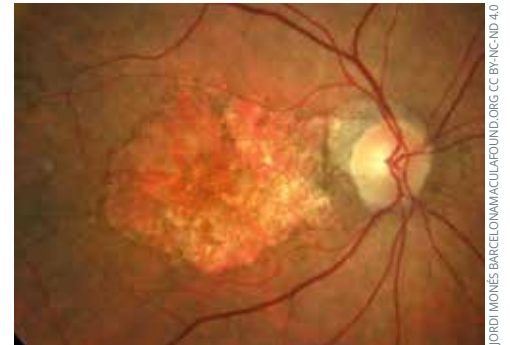**Figure 3** Drusen in early AMD, seen using an ophthalmoscope.



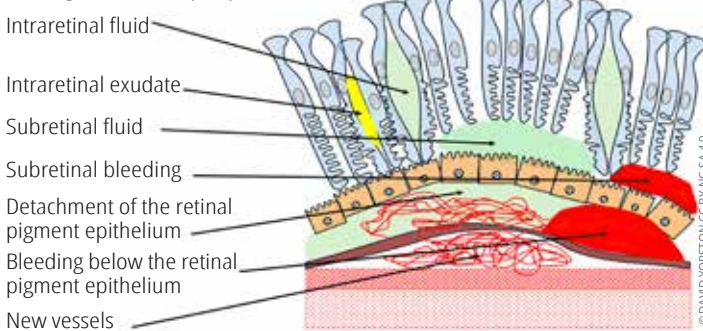
**Figure 4: Advanced AMD: atrophic (dry) type.** There is atrophy of the retinal pigment epithelium and choriocapillaris, with resulting loss of photoreceptors.



**Figure 5** Atrophy (pale area) in a patient with dry AMD.



**Figure 6: Advanced AMD: neovascular (wet) type.** New vessels have grown from the choriocapillaris into the space under the retinal pigment epithelium. Note the distorted and misaligned photoreceptors, leading to metamorphopsia.

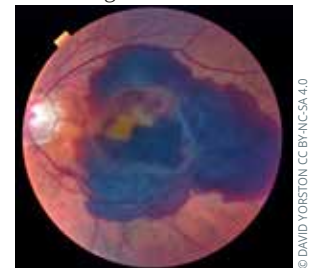


## Clinical features

The clinical features of advanced AMD are easily detected by examining the macula with an ophthalmoscope. However, the early changes can be more subtle.

The earliest visible sign of AMD is **drusen** (Figure 3). Small drusen are common and have no clinical significance. However larger drusen – 100 microns or more – are an indication that the outer retinal complex is damaged. There may be retinal pigment epithelium migration into the retina, visible as black spots. If the AMD is primarily atrophic, there will be **pale areas** or atrophy (Figure 5), caused by loss of RPE and choriocapillaris. If there are macular new vessels, you may see **oedema** and **intra-retinal or sub-retinal fluid**. If the vessels continue to leak, there are likely to be **exudates**, and there may be **bleeding under the retina** (Figure 7). Ultimately, the macula is replaced by white scar tissue.

**Figure 7** Submacular haemorrhage in advanced neovascular AMD. Note that the blood vessels are visible above the bleeding, confirming that it is subretinal.



## Prevention

Reducing genetic risk is impossible, unless you can choose your parents! However, stopping smoking is valuable. Twenty years after quitting, an ex-smoker's risk of AMD is the same as that of a non-smoker. Dietary measures may help, but the evidence is unclear. A diet that is low in fats, but high in fish and vegetables, may reduce the risk of AMD. Regular exercise and avoiding obesity also seem to reduce the risk. A large clinical trial (AREDS – Age-Related Eye Disease Study) showed that daily high doses of antioxidants – specifically vitamin C (500mg), vitamin E (400IU), zinc (80mg) and copper (2mg) – reduced the risk of AMD progression by about 25% in patients who already had severe AMD in one eye. However, there was no beneficial effect in patients with early AMD. These doses of vitamins far exceed the normal dietary levels – for example, the recommended minimum daily intake of vitamin C is around 100mg – and can only be achieved by taking tablets.

## Symptoms

The main symptom of AMD is loss of central vision. Unlike glaucoma, or diabetic retinopathy, where advanced disease may be asymptomatic, significant AMD will always cause reduced visual acuity in the affected eye.

In **atrophic AMD**, the loss of vision is likely to be slow and gradual, extending over months or years. Because the photoreceptors are not displaced, there are usually no symptoms of distortion.

In **neovascular AMD**, loss of vision is usually more rapid, occurring over days or weeks, and can happen suddenly – particularly if there is a haemorrhage under the retina. In the initial stages, when fluid leaks into or under the retina, the photoreceptors are displaced, causing distortion or metamorphopsia. This is an important symptom of macular disease but the patient may not think to mention it. You should always ask about distortion, and, if the patient is unsure, test for it by asking them to look at a straight line, such as a doorway or window frame. You don't need special charts or instruments to detect whether metamorphopsia is present. Quantifying metamorphopsia is more complex, and probably not essential in the management of AMD.

## Investigations

For atrophic AMD, very precise measurements of the extent of the atrophy can be obtained with autofluorescence. A photograph of the retina is taken using blue light (488nm). This causes the lipofuscin in the RPE cells to fluoresce. Where there is atrophy of the RPE, it shows up as a dark area in the image. In practice, autofluorescence imaging is not necessary to make a diagnosis of atrophic AMD, but it may be useful for measuring progression.

The most useful investigation for AMD is optical coherence tomography (OCT). This is covered in more detail on pp. 15–16. Essentially, OCT uses low powered infrared lasers to create a detailed cross-sectional image of the retina. This demonstrates atrophy and loss of photoreceptors, and/or intra-retinal or sub-retinal fluid. OCT angiography (OCT-A) bounces the laser off moving red cells, and uses the signal this generates to create a detailed image of the retinal circulation, including any abnormal vessels growing from the choroid. OCT is safe and takes about five minutes per patient. This means that it can be repeated at each clinic visit, and used to follow the response to treatment or to indicate when treatment needs to be increased.

## Treatment

Anti-VEGF drugs (see page 10) are effective against neovascular AMD, but have no effect on atrophic AMD, which usually co-exists with neovascular AMD. Most patients with treated neovascular AMD will therefore still experience a gradual loss of visual acuity over several years. We must ensure that low vision and supportive services are available to these patients.





**Rajiv Raman**  
Senior Consultant:  
Shri Bhagwan  
Mahavir Vitreoretinal  
Services, Sankara  
Nethralaya, Chennai,  
India; Professor of  
Practice: Department  
of Medical Science  
and Technology,  
IIT-Madras, Chennai,  
India; Visiting  
Professor : Vision  
and Eye Research  
Unit, Anglia Ruskin  
University,  
Cambridge, UK



**Raja Narayanan**  
Director: Anant Bajaj  
Retina Institute, L.V.  
Prasad Eye Institute,  
Hyderabad, India.

# Diabetic macular oedema (DMO): an introduction

DMO is a complication of diabetes that requires a collaborative approach for both early detection and long-term management.

The number of people affected by diabetes is continuing to rise worldwide. Diabetes causes high blood sugar levels, which damages blood vessels and nerves in various tissues, resulting in complications such as cardiovascular disease, kidney disease, foot problems (sometimes resulting in amputation), and damage to the retina, known as diabetic retinopathy.

Diabetic macular oedema (DMO) is a complication of diabetic retinopathy and occurs when vascular endothelial growth factor (VEGF) and other inflammatory factors alter the blood-retinal barrier. This causes leakage of fluid around the macula – the area responsible for central vision – causing retinal thickening and exudation. The resulting distortion and reduction in central vision can profoundly impact people’s quality of life, restricting key daily activities.

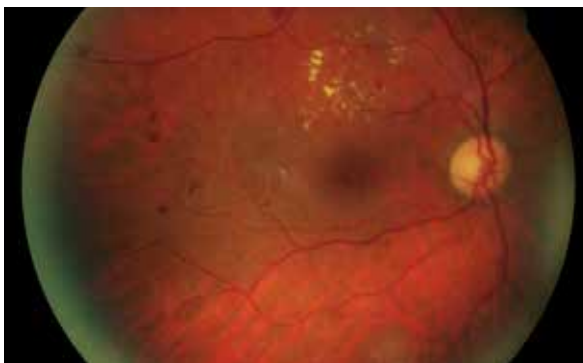DMO is the most common cause of sight loss in people with diabetes. Key risk factors include prolonged diabetes duration, poor blood sugar control, high blood pressure, and hyperlipidemia.<sup>1</sup>

## Community/primary level

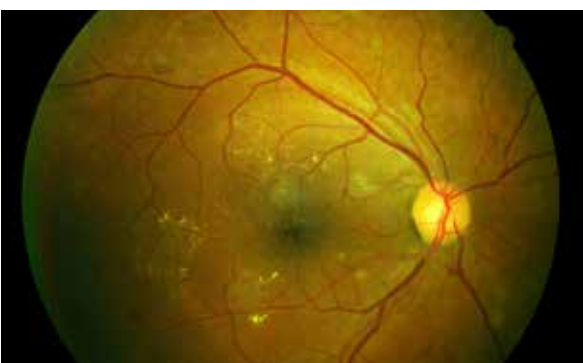Suspect that a patient has DMO if:

- they have diabetes
- they report loss of vision
- they report distortion of vision
- they have other complications of diabetes, such as foot damage

**Figure 1** Mild DMO



**Figure 2** Moderate DMO



Primary care providers should refer patients with suspected DMO for an eye examination by an ophthalmologist.

## Clinical examination

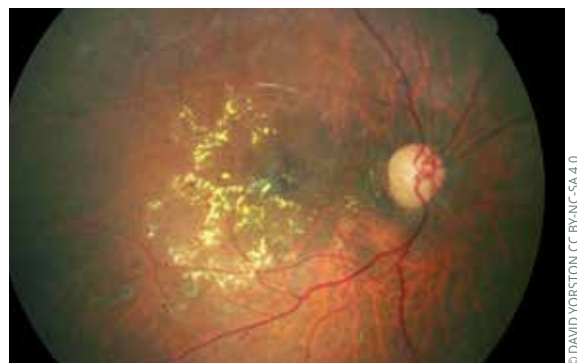
Diabetic macular oedema can be detected in different ways, depending on the personnel and equipment available.

- 1 **Dilated fundus examination.** Using a direct ophthalmoscope, perform a careful fundus examination through dilated pupils to inspect the retina for signs of diabetic retinopathy and macular oedema. Dilating the pupil is essential, as it allows examination of the macula, enabling the detection of retinal thickening, hard exudates, and other signs indicative of DMO.
- 2 **Slit lamp biomicroscopy with a handheld lens.** This method allows detailed, and three-dimensional, visualisation of the macula using a slit lamp and a 90D or 78D lens. This technique is ideal for identifying changes in the macula and subtle signs of diabetic macular oedema.
- 3 **Fundus photography.** Photographing the retina to detect and document changes over time.
- 4 **Telemedicine and remote screening tools.** In resource-limited settings, teleophthalmology can be used to examine patients remotely. Images captured by non-mydriatic cameras in primary care centres can be sent to a specialist for evaluation.
- 5 **OCT.** OCT is valuable for detecting and quantifying retinal thickening and fluid accumulation characteristic of DMO.

## Clinical features

Diabetic macular oedema is characterised by retinal thickening and the presence of hard exudates. The severity is categorised as mild (Figure 1), moderate (Figure 2), or severe (Figure 3) based on the location and extent of these lesions. Mild DMO features retinal changes more than two thirds of a disc diameter (1,000µm) from the central macula. Moderate DMO involves lesions close to but not involving the fovea,

**Figure 3** Severe DMO



whereas severe DMO includes lesions that affect the fovea, posing a significant threat to central vision.<sup>2</sup>

Patients with moderate or severe diabetic macular oedema should be referred to an eye specialist, who will classify DMO into centre-involving and non-centre-involving DMO using clinical criteria. Centre-involving DMO generally requires active treatment, such as intravitreal injections using anti-VEGF drugs (see page 10 in this issue). In contrast, non-centre-involving DMO may be managed by observation and reducing the risk of progression through improved control of blood sugar and blood pressure. For some patients, laser treatment may be useful, if it is available.

Regular follow-up is critical to monitor DMO and to adjust treatment as necessary.

### **Patient education and self-monitoring**

Educating patients with diabetes about the early symptoms of DMO is crucial. Common symptoms to monitor include blurred vision or distorted vision, where straight lines may appear wavy or bent. Additionally, colours may appear faded or washed out, and dark spots or blank areas might obscure the central field of vision.

Patients should be encouraged to monitor their own vision using tools like the Amsler grid (if available) or by looking at a straight doorway or window frame to help detect visual distortions early. They should report any changes in vision to their healthcare provider promptly. If a screening programme exists, all people with diabetes should be encouraged to take advantage of this. Retinal photography is effective at detecting DMO before any sight is lost, and early detection and treatment leads to better outcomes.

### **Screening, referral and effective management**

Diabetic retinopathy, especially in adults, is a slowly progressive condition. Typically, it takes decades after detecting the early signs of diabetic retinopathy before someone develops sight-threatening diabetic retinopathy, including diabetic macular oedema. Screening people with diabetes for early signs of retinopathy means that there is time to act before vision impairment develops.

A strong referral system is crucial. Eye health workers should know when, where, and how to refer patients who have potentially sight-threatening retinopathy. Ophthalmologists who are able to treat diabetic

retinopathy should ensure that all local clinics are aware of the service offered, and understand the referral pathway.

Effective management of DMO depends on collaboration between primary care providers and eye care specialists. Clear communication and coordination will ensure patients receive timely and appropriate care.

### **Risk factor management and prevention**

Effective management of DMO involves addressing systemic conditions that exacerbate the condition. Apart from good control of blood sugar, other interventions may help to control or prevent DMO. Anaemia accelerates diabetic complications and DMO progression and should be managed. Dyslipidemia (high blood cholesterol) significantly contributes to DMO, and lipid-lowering drugs like fenofibrate have been shown to reduce DMO severity irrespective of actual lipid levels.<sup>3</sup> Managing renal disease is crucial, as nephropathy correlates strongly with DMO outcomes, influencing treatment responses.<sup>4</sup>

Cardiovascular diseases also interact with DMO. Good control of blood pressure reduces the risk of DMO, and cardiovascular disease – particularly ischaemic heart disease or stroke – may be a contra-indication to anti-VEGF injections.<sup>5</sup> Obstructive sleep apnoea exacerbates retinal damage through intermittent hypoxia, and should be treated if possible. A holistic approach to managing these systemic factors is valuable for effective DMO treatment and prevention.

### **Conclusion**

DMO is a significant complication of diabetes. It affects vision through breakdown of the blood retinal barrier, leading to retinal thickening and exudates, which affect visual acuity when the fovea is involved. Early detection at primary level is crucial, using the strategies described in this article. Managing DMO requires a multidisciplinary approach involving primary care providers and eye specialists for timely referrals, follow-up care, and tailored treatment plans. Patient education on self-monitoring and lifestyle adjustments is vital to manage risk factors and prevent progression. This collaborative approach is essential for preserving vision and improving patient quality of life.

### **References**

- 1 Wang Y, Lin Z, Zhai G, et al. Prevalence of and Risk Factors for Diabetic Retinopathy and Diabetic Macular Edema in Patients with Early- and Late-Onset Diabetes Mellitus. *Ophthalmic Res.* 2022;65(3):293-9. doi:10.1159/000508335.
- 2 Diabetic Macular Oedema: Diagnosis and Management. AAO <https://www.aao.org/eyenet/article/diabetic-macular-oedema-diagnosis-and-management> (Last accessed on 3/5/2024).
- 3 Keech AC, Mitchell P, Summanen PA, et al. Effect of fenofibrate on the need for laser treatment for diabetic retinopathy (FIELD study): a randomised controlled trial. *Lancet.* 2007;370(9600):1687-97.
- 4 Thomas MC. Anemia in diabetes: marker or mediator of microvascular disease? *Nat Clin Pract Nephrol.* 2007;3(1):20-30. doi:10.1038/ncpneph0378.
- 5 Xie J, Ikram MK, Cotch MF, et al. Association of Diabetic Macular Edema and Proliferative Diabetic Retinopathy With Cardiovascular Disease: A Systematic Review and Meta-analysis. *JAMA Ophthalmol.* 2017;135(6):586-93. doi:10.1001/jamaophthalmol.2017.0988.
- 6 Network TDRRC. Aflibercept, bevacizumab, or ranibizumab for diabetic macular oedema. *N Engl J Med.* 2015;372:1193-203. doi.org/10.1056/NEJMoa1414264.



**Michael Mikhail**  
Consultant  
Ophthalmologist  
and Vitreoretinal  
Surgeon: Kabgayi  
Eye Unit, Muhanga,  
Rwanda and Senior  
Lecturer: College of  
Medicine and  
Pharmacy, University  
of Rwanda.

# Anti-VEGF treatment for macular conditions

The introduction of anti-VEGF drugs has revolutionised the management of macular conditions that were previously untreatable.

**V**EGF stands for vascular endothelial growth factor. It is a protein that plays a critical role in the growth and development of new blood vessels. VEGF production is increased by a lack of oxygen. Once tissues (e.g. in the retina) sense the lack of oxygen, more and more VEGF is produced, leading to growth of new blood vessels in an attempt to provide more oxygen to the tissues. However, VEGF also increases the permeability of fine blood vessels (capillaries), so these new blood vessels tend to be abnormal and bleed or leak fluid and proteins into the surrounding tissue. In diseases of the macula, like age-related macular degeneration and diabetic macular oedema, VEGF is often overproduced, leading to retinal damage and several blinding complications.

The introduction of anti-VEGF drugs given as intravitreal injections, has revolutionised the treatment of these previously untreatable conditions. Many patients can now achieve a reasonable visual acuity, especially with early diagnosis and timely treatment. The most commonly used anti-VEGF drugs are bevacizumab (Avastin), ranibizumab (Lucentis), and aflibercept (Eylea). These three medications have been in use for more than a decade, with proven safety and efficacy in treating age-related macular degeneration and diabetic macular oedema.

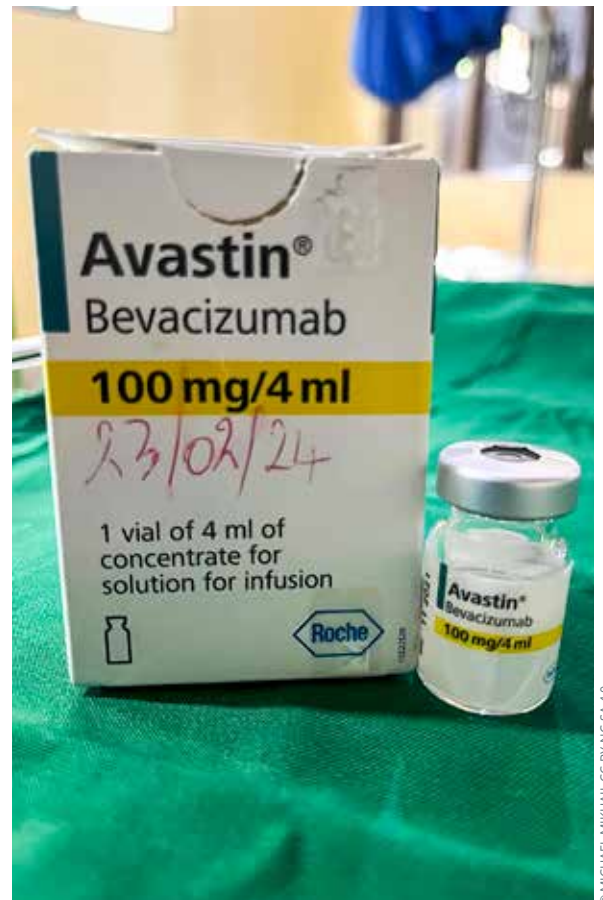## Limitations and challenges

Because anti-VEGF drugs do not cure the underlying pathology, patients need repeated injections and regular monitoring, and their treatment may have to be continued indefinitely.

In low-income settings, affording anti-VEGF treatment remains a challenge. The cost of anti-VEGF drugs is still relatively high, and many eye units rely on bevacizumab (Avastin) due to its lower cost, making it more affordable for our patients, with comparable outcomes to other anti-VEGF drugs.<sup>1</sup> However, more frequent administration is required, and the cost of multiple clinic visits means that many people cannot afford ongoing treatment.

## Reference

- 1 How do anti-vascular endothelial growth factors (anti-VEGFs) compare with one another for people with diabetic macular edema? Sera Tort (MD) and Sarah Anderson (MBChB) (on behalf of Cochrane Clinical Answers Editors). Cochrane Clinical Answers 2023. DOI: 10.1002/cca.4368.



Many eye units still rely on bevacizumab (Avastin) due to its lower cost.

In high-income settings, cost is less of an issue. However, many eye units are struggling to keep up with the demands of providing multiple injections and regular review for the growing number of patients benefiting from anti-VEGF treatment. This has prompted the search for new anti-VEGF drugs that can reduce the number of clinic visits each patient needs. Two new drugs that can increase treatment intervals to 12 or even 16 weeks are faricimab (Vabysmo 6 mg), and an increased 8mg dose of aflibercept (Eylea). Other advances are underway and yet to be licensed. One of these is the port delivery system (PDS) by Roche: an implant surgically placed through the ciliary body which acts as a reservoir of ranibizumab that is refilled every 6 months. Several companies are working on administering relevant drugs as eye drops; this would either avoid the need for injections or lengthen the interval between them.

Anti-VEGF biosimilars are highly similar versions of 'originator' drugs like bevacizumab (Avastin) and ranibizumab (Lucentis). Biosimilars are designed to provide the same safety, quality, and efficacy but at a lower cost, making them ideal for resource-limited settings. However, to the best of my knowledge, they are not yet available in most African countries, including Rwanda. Their introduction could significantly improve access and affordability of retinal care across the continent.

## Treatment regimen for established anti-VEGF drugs

Anti-VEGF drugs need to be given in the long term for best results. All of them require a loading dose of 3–4 injections, spaced 4 weeks apart. After the loading dose, review patients and discuss a further treatment regimen (this is usually one injection every 8 weeks for aflibercept and faricimab).

**Note:** The dose and frequency of administration is the same for diabetic macular oedema and neovascular age-related macular degeneration.





**Anthony Hall**  
Consultant  
Ophthalmologist:  
Hunter Eye  
Surgeons,  
Newcastle,  
Australia.

# Surgical maculopathies: epiretinal membranes and full-thickness macular holes

Epiretinal membrane and full-thickness macular hole are common and treatable conditions of the retina. Left untreated, they can lead to profound loss of central vision, but with prompt and effective surgery, most patients will achieve significant improvements in visual acuity and distortion.

**S**urgery offers hope to patients affected by epiretinal membrane and full-thickness macular hole, both of which result in loss of central vision. Epiretinal membranes and full-thickness macular holes are both associated with vitreous detachment, usually in people during their 60s or 70s. It is important to recognise them as they can affect vision, and effective treatment is available. They often coexist with cataract, which may make them difficult to detect and lead to disappointing visual outcomes from cataract surgery.

## How patients present

Patients with **epiretinal membranes** present with symptoms such as reduced central visual acuity, blurring, metamorphopsia (distortion of straight lines), aniseikonia (different-sized images) and loss of stereopsis. Vision loss is gradual and may not be noticed by patients.

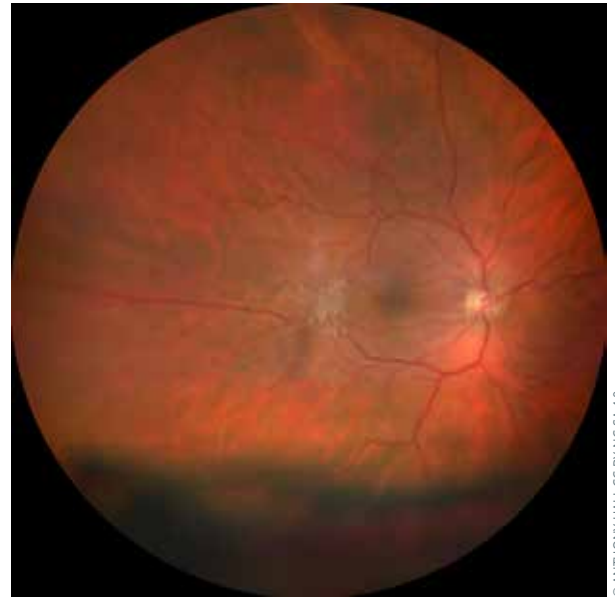
Unlike epiretinal membranes, which come on quite slowly, patients with **full-thickness macular holes** present with fairly acute loss of central vision, as full-thickness macular holes occur quite rapidly. If a patient presents with reduced central vision and the lens is still relatively clear, it is mandatory to examine the macula and look for a full-thickness macular hole, as prompt diagnosis and referral can restore vision to normal.

Full-thickness macular hole is three times more common in women than in men. Epiretinal membrane is also slightly more common in women. Large population-based studies found a prevalence of epiretinal membrane of between 7% and 11.8% using fundus photographs, but this increased to 34% when optical coherence tomography (OCT) was used. Full-thickness macular hole is less common, occurring in between 0.2 to 3.3 per 1,000 population.<sup>1</sup> As both these conditions are uncommon in patients under 60, their prevalence will be lower in countries with a younger population.

## Epiretinal membrane

Epiretinal membrane may be primary or secondary. Primary epiretinal membrane occurs when there is no risk factor other than a posterior vitreous detachment. Secondary epiretinal membrane occurs in conjunction with other eye diseases, most commonly diabetic retinopathy, retinal vein occlusion, or retinal tears/detachment.<sup>2</sup>

Clinical grading, based on photographs or slit lamp examination, may be divided into cellophane maculopathy, which is an early translucent epiretinal membrane without distortion of the retina, and macular pucker, or preretinal



**Figure 1** The epiretinal membrane is the white patch temporal to the fovea. This is an area of fibrous tissue which is contracting. The contraction has drawn the blood vessels of the superior and inferior arcades towards the membrane. Traction lines can be seen as folds in the retina, starting near the disc and crossing the fovea, going towards the epiretinal membrane.

fibrosis, which is a more advanced form of epiretinal membrane, causing distortion of the inner retina.

## History and examination

Enquire about diabetes, previous ocular trauma, and a history of flashing lights and floaters. Many patients with early epiretinal membrane are asymptomatic and the membrane may be identified at routine examination. Vision may be affected by traction, retinal oedema, or an opaque membrane.

Early membranes can be seen as a glistening light reflex over the macula (Figure 1). As the membrane progresses, the retinal surface is wrinkled (Figure 2), and blood vessels become more tortuous or straightened. It may also be possible to detect cystoid macular oedema, loss of the foveal reflex, pseudoholes, and full-thickness macular holes.

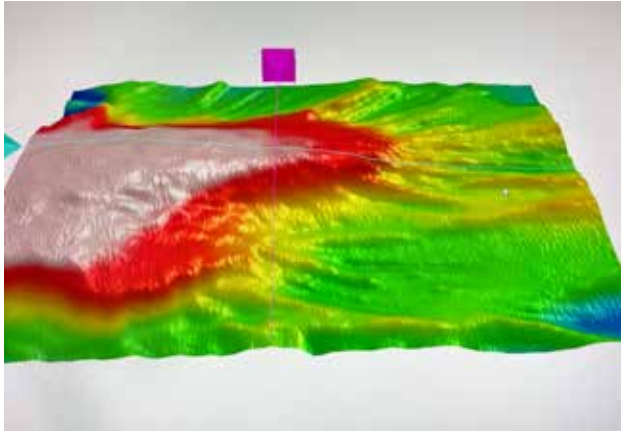
## Investigations

Optical coherence tomography (OCT) examination is invaluable in diagnosing, managing, and following patients with epiretinal membrane and macular holes. It is able to detect associated conditions like lamellar macular holes (a foveal cavity with undermined edges and loss of foveal tissue) and foveoschisis (separation of the foveal layers).

## Treatment

Most patients with epiretinal membrane will not require any treatment. Progression of epiretinal membrane is uncommon, and, if the patient is asymptomatic, they may be discharged and advised to return if their vision gets worse. Surgery for epiretinal membrane is performed when patients' visual loss or symptoms affect their activities of daily living. The goal of surgery is to

**Figure 2** An OCT retinal thickness map demonstrates how the thick contracting membrane has elevated the retina temporally and is causing traction folds in the surrounding retina.



© ANTHONY HALL CC BY-NC-SA 4.0

stabilise or improve vision and to reduce metamorphopsia. If you are unsure if a patient needs to be referred, ask them “Do you close your bad eye in order to see better with the good eye?” If they do, it is worth referring them to a retinal surgery centre.

Surgery consists of pars plana vitrectomy and removal of the epiretinal membrane, which may be combined with peeling of the internal limiting membrane. The surgeon uses a blue dye to stain the membranes and then peels them away from the macula with microforceps.

**Complications**

All patients having vitrectomy for full-thickness macular hole or epiretinal membrane should be told that they will develop a cataract. Indeed, many surgeons combine cataract extraction with the vitrectomy. Patients should be warned of the risk of retinal detachment, haemorrhage, endophthalmitis, and hypotony, but these complications are rare.

**Prognosis**

On average, vision improves by two lines of visual acuity. The greatest improvement is seen in patients with poor pre-operative visual acuity, but the final visual acuity is better in those with a better pre-operative visual acuity. Patients also get relief from metamorphopsia. The reduced distortion improves binocular vision, making it easier for the two eyes to work together. Patients usually report an improvement in their vision-related quality of life, even if there is only a small improvement in visual acuity. Following surgery, visual improvement is slow and may take up to 3 years.

**Full-thickness macular hole**

Full-thickness macular hole is a defect in the fovea that involves all the neurosensory layers of the retina, from the internal limiting membrane down to the photoreceptor layer (Figure 3). Untreated, this is associated with severe central visual impairment. Full-thickness macular hole may be primary (caused during vitreoretinal detachment) or secondary. Causes of secondary full-thickness macular hole include trauma, severe myopia, and retinal detachment.

**Distinguishing pseudoholes from full-thickness holes**

A pseudohole is a circular defect in the epiretinal membrane overlying the fovea, and it resembles full-thickness macular hole.

The visual acuity is usually 6/36 or worse in full-thickness macular hole, but rarely worse than 6/24 in pseudoholes. Always check the peripheral retina carefully to detect untreated retinal tears, and look for signs of vein occlusion or diabetic eye disease.

**Diagnosis**

On presentation, depending on the duration of the macular hole, central visual acuity will range from 6/9 in very early, small holes, to counting fingers for long-standing, neglected holes. Macular holes can be diagnosed by careful slit lamp examination, but the signs are subtle (Figure 4). OCT scans are recommended.

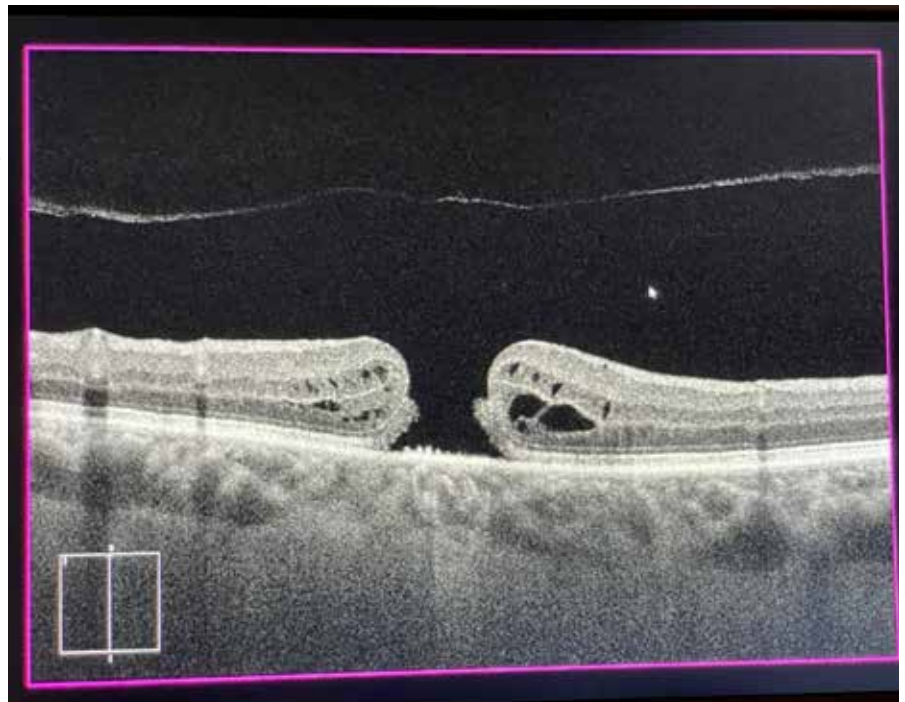
**Pathogenesis**

As the vitreous starts to detach, it pulls on the fovea. A combination of this antero-posterior traction and tangential traction from the elastic internal limiting membrane leads to a full thickness hole. The edges of the hole become hydrated, leading to macular oedema.<sup>3</sup>

**Classification**

The International Vitreomacular Traction Study Group proposed OCT-based staging (Duker et al., 2013). The two stages depend on the presence (early stage) of vitreomacular traction or its absence (late stage). Further subgroups, based on size measured at the narrowest point of the hole, are: small (< 250µm), medium (> 250µm and < 400µm), large (>400µm). However, recent studies show that there is little difference in prognosis between 350µm and 450µm holes. We should therefore probably regard holes from 250-500µm as medium, and large holes as any hole >500µm.

**Figure 3** The HD OCT scan of the macular hole shows the separation of all the retinal layers at the fovea down to the RPE. The retina surrounding the hole has become oedematous with cystic spaces visible in the retinal layers.



© ANTHONY HALL CC BY-NC-SA 4.0

## Treatment

Patients with recent-onset full-thickness macular hole, in particular, will benefit from prompt diagnosis and referral.

Surgery for full-thickness macular hole is similar to that for epiretinal membrane, with a few important differences. A posterior vitreous detachment often has to be induced. Triamcinolone acetonide microparticles can stain the vitreous, making it easier to see. Inducing a posterior vitreous detachment carries a risk of retinal tears. The peripheral retina must be inspected very carefully and any tears treated.

Peeling the internal limiting membrane has been proven to increase the success rate of full-thickness macular hole surgery. In large and refractory holes (holes that have not closed with surgery), internal limiting membrane flaps can be used to plug the hole to improve healing. Once the vitrectomy is completed, the eye is filled with a gas. Short-acting gases such as SF<sub>6</sub> are used with smaller holes, while longer-acting gases such as C<sub>3</sub>F<sub>8</sub> improve the outcome with larger holes. Maintaining a strict face-down position after surgery is difficult for most patients, and we have found that – as long as the eyes are looking down all the time, the outcome for small to medium holes is excellent without the patient needing to maintain a face-down posture. There is little benefit from maintaining an eyes-down or face-down posture for longer than 3 days, even for patients with larger holes.

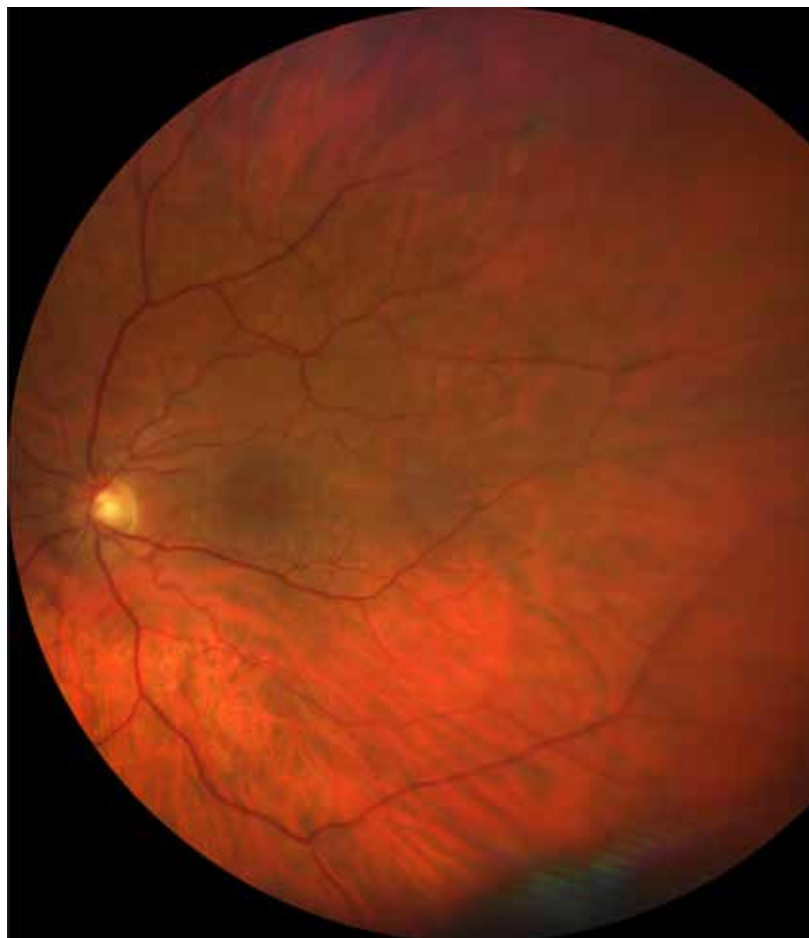
## Prognosis

The prognosis is excellent for small/medium holes with a short duration. An estimated 95% of holes smaller than 500 µm are closed with a single operation. The average vision improvement is approximately 0.5 LogMAR units, equivalent to a change from 6/36 to 6/12. Large, chronic holes are more difficult to treat, and even when they are successfully closed, the vision may not improve as much.

## References

- 1 Duker JS, Kaiser PK, Binder S, et al. The International Vitreomacular Traction Study Group classification of vitreomacular adhesion, traction, and macular hole. *Ophthalmology*. 2013;120(12):2611-2619. doi:10.1016/j.ophtha.2013.07.042
- 2 Fung AT, Galvin J, Tran T. Epiretinal membrane: A review. *Clin Exp Ophthalmol*. 2021;49(3):289-308. doi:10.1111/ceo.13914
- 3 Premi E, Donati S, Azzi L, et al. Macular Holes: Main Clinical Presentations, Diagnosis, and Therapies. *J Ophthalmol*. 2022;2022:2270861. Published 2022 Apr 11. doi:10.1155/2022/2270861

**Figure 4** A colour photograph of the macular hole, showing how the central changes can be quite subtle. The cuff of oedema around the hole can be seen.



© ANTHONY HALL CC BY-NC-SA 4.0

## How epiretinal membranes and macular holes develop

As people get older, the vitreous gel in the eye starts to degenerate. The posterior surface of the gel separates from the back of the eye and moves forward, towards the front of the eye. This is known as a posterior vitreous detachment. As the gel moves forwards, it can tear the peripheral retina, which can lead to **retinal detachment**.

Sometimes, a posterior vitreous detachment can result in conditions that affect **central** vision: epiretinal membrane and full-thickness macular hole.

In **epiretinal membrane**, the cells left behind or deposited on the surface of the retina after the vitreous detaches proliferate and – as the tissue contracts – this causes distortion and thickening of the macula.

The detaching vitreous may also pull on the fovea. A combination of anterior-posterior traction and tangential traction from the elastic internal limiting membrane results in a separation of all the layers of the retina, right through to the photoreceptor layer (outer retina), known as a **full-thickness macular hole**. There is no loss of retinal tissue, but the separation of retinal tissue means a loss of central vision. This can be restored if the hole is closed.

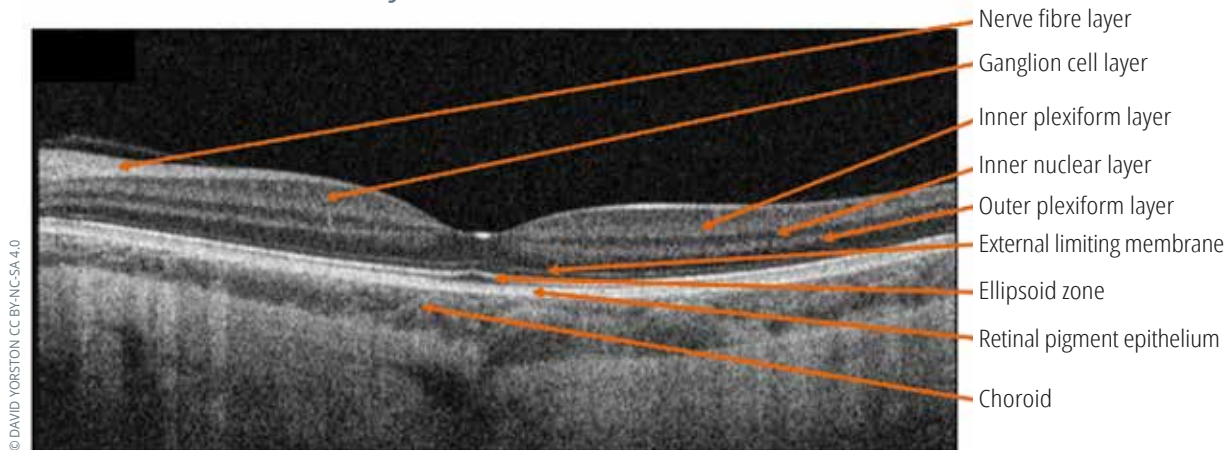




**David Yorston**  
Consultant  
Ophthalmologist,  
Tennent Institute of  
Ophthalmology,  
Gartnavel Hospital,  
Glasgow, Scotland.

# Optical coherence tomography: an introduction

OCT scans support the diagnosis of macular conditions by allowing us to see the thickness of individual layers of the retina.



**Figure 1: Normal anatomy of the macula on OCT.** The photoreceptors are represented by the outer plexiform layer, external limiting membrane and the ellipsoid zone. The ellipsoid zone is the junction between the photoreceptor cell bodies and the outer segments of the photoreceptors. If it is absent, there are no photoreceptor outer segments present. The central depression is the foveal pit and is a normal feature of a healthy macula.

In 1991, researchers at the Massachusetts Institute of Technology described a method using low intensity laser light to obtain an image of the retina. Because the system used light, it was called optical; because it used light from a laser source, in which the light is “coherent” – i.e. all the light waves are parallel and in step – they called it coherent. Because the image is a cross section, they called it tomography – ending up with the name optical coherence tomography or OCT.

OCT is convenient and comfortable for the patient: it only uses low-intensity light (it is much less bright than the light from an ophthalmoscope or slit lamp), it is not always necessary to dilate the pupil in order to obtain a satisfactory image, and the scanning process takes only a few seconds.

The first OCT devices were available at the turn of the century, but they acquired images slowly and with limited detail, scanning the retina at a frequency of 400 sweeps per second. The ‘spectral domain’ OCT devices now in common use acquire images much more quickly, with a scanning frequency of over 25,000 sweeps per second, which gives a resolution of less than 10 microns. The very latest OCT machines are able to detect the movement of individual red blood cells in the retinal capillaries, which enables ophthalmologists to obtain very detailed images of the retinal circulation, called OCT-angiography (OCT-A). These devices can detect macular new vessels, new vessels of the retina, or the absence of capillaries in retinal ischaemia.

## How does OCT work?

The retina contains multiple layers of tissue of different densities. The OCT machine directs laser light at the

retina, which is bounced off the different layers and the interfaces between them. A sensor gathers data about the reflected light by comparing the reflected light beam to a reference beam, which is reflected off a plain mirror. An image processing computer then converts the data into a usable image using a complicated algorithm which is beyond the scope of this article to explain.

**“OCT scans provide us with an extraordinarily detailed image of the central retina.”**

OCT scans provide us with an extraordinarily detailed image of the central retina. We can measure the thickness of the macula and establish in which layer the abnormalities, such as fluid or exudate, are present. Changes in thickness can also be measured and

monitored. Increased thickness may be due to age-related macular degeneration (AMD), diabetic maculopathy, or macular oedema (related to any other vascular or inflammatory diseases), and a reduction in thickness might be related to loss of tissue, such as geographic atrophy in AMD.

Some layers of the retina are **hyporeflexive** – they don’t reflect much light, so appear darker on OCT. The ganglion cell layer, which contains the cell bodies of the optic nerve cells, looks dark on OCT. Fluid, either within or under the retina, is also hyporeflexive and therefore dark on OCT.

Other layers are **hyperreflexive** – they reflect light, and so appear brighter on OCT. The ellipsoid zone – which represents the junction between the photoreceptor outer segments and the photoreceptor cell bodies – usually shows up as a bright white line. Exudates are also hyperreflexive and appear white on OCT.

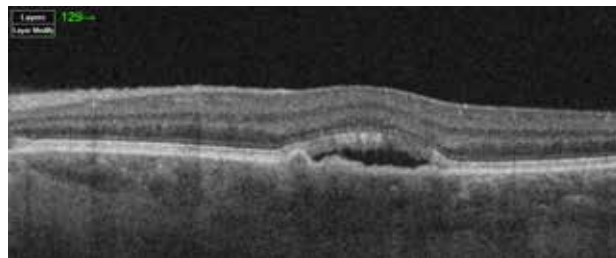OCT is used most commonly to show a detailed cross-section of the central retina. In addition, it can image the optic nerve, and is therefore a useful tool to detect the loss of optic nerve fibres in glaucoma.

The ability of OCT to measure the thickness of the different retinal layers accurately makes it useful outside ophthalmology. For example, reductions in nerve fibre layer thickness are associated with

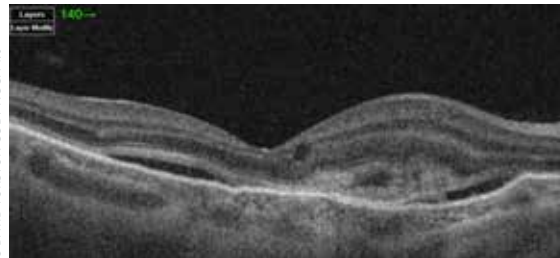
neurodegenerative conditions such as Alzheimer's or Parkinson's disease. Early identification of people who may be at risk may allow preventive treatments to be given sooner, when they may be more effective.

Although the physics and technology of OCT are complex, the basic skills for interpreting the images can be learnt relatively quickly. Figure 1 shows the normal anatomy of the macula; Figures 2–7 are examples of common macular conditions.

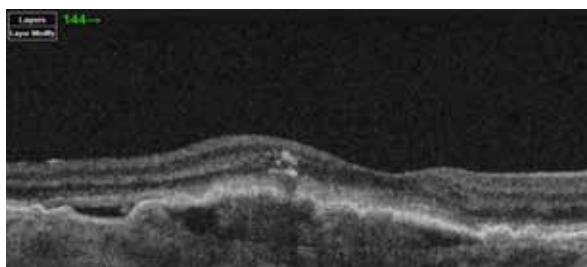**Figure 2: Early exudative AMD.** There is sub-retinal fluid, and the retinal pigment epithelium is irregular. The fibrovascular scar tissue cannot be seen at this stage.



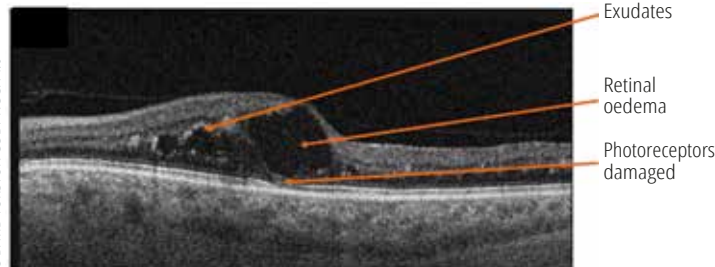
**Figure 3: Exudative AMD.** The OCT scan shows fluid under the retina. The sub-retinal neovascular membrane is seen to the right of the fovea.



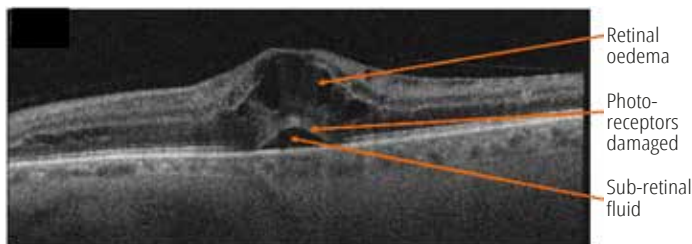
**Figure 4: Exudative AMD.** There is fluid under the retina, and the fibrovascular membrane can be seen under the retinal pigment epithelium. The hyperreflective white spots in the retina are exudates.



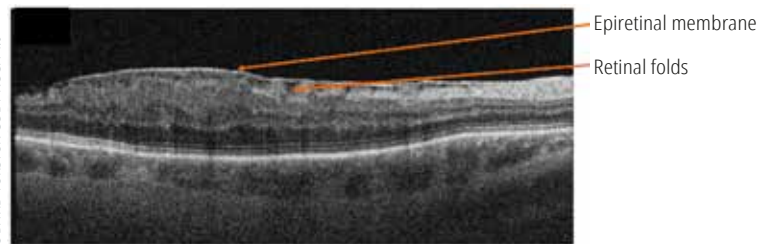
**Figure 5a: Diabetic macular oedema.** The retina is thickened and oedematous. Unlike the thickening caused by the epiretinal membrane, all layers of the retina are affected. The larger white hyperreflective spots are hard exudates (the small ones are hyperreflective foci).



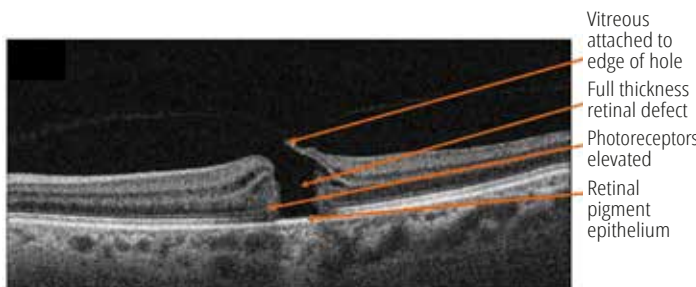
**Figure 5b: Diabetic macular oedema.** The retina is thickened and elevated. Fluid has accumulated within the layers of the retina and under the fovea. The ellipsoid zone is not visible where the retina is most affected.



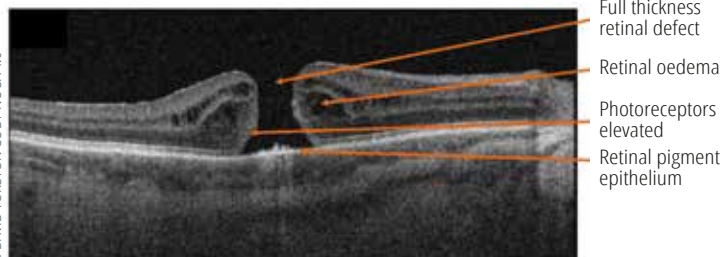
**Figure 6: An epiretinal membrane.** There is a hyperreflective membrane on the retinal surface. The inner retina is wrinkled and thickened, and the normal inner layers are not clearly defined. The photoreceptors and retinal pigment epithelium are unaffected.



**Figure 7a: A macular hole.** The scan shows complete loss of all retina layers, from the vitreous to the retinal pigment epithelium.



**Figure 7b: A macular hole.** The vitreous is separated from the macular hole, and there are fluid-filled cysts within the retina, causing swelling of the retina surrounding the hole.





**Barbara Parolini**

Head of Vitreoretinal Unit Eyecare Clinic, Brescia, Italy.

# Management of myopic traction maculopathy

High myopic eyes with myopic traction maculopathy were expected to improve only anatomically after surgery. With early detection and appropriate treatment, however, visual acuity can improve by an average of two lines.

**M**yopia, or short sightedness (defined as more than or equal to 0.50 D of myopia) is the leading cause of refractive error, affecting 35% of the population in 2023.<sup>1</sup>

Genes have been identified for myopia<sup>2-5</sup> that are thought to determine one's susceptibility to environmental factors, including too much time spent on near work,<sup>5</sup> insufficient time spent outdoors, low levels of vitamin D,<sup>6</sup> inadequate light exposure, and poor diet. There is evidence emerging that increased time spent outdoors can reduce the risk of developing myopia and – in those with myopia – it can reduce the rate of progression.<sup>5</sup>

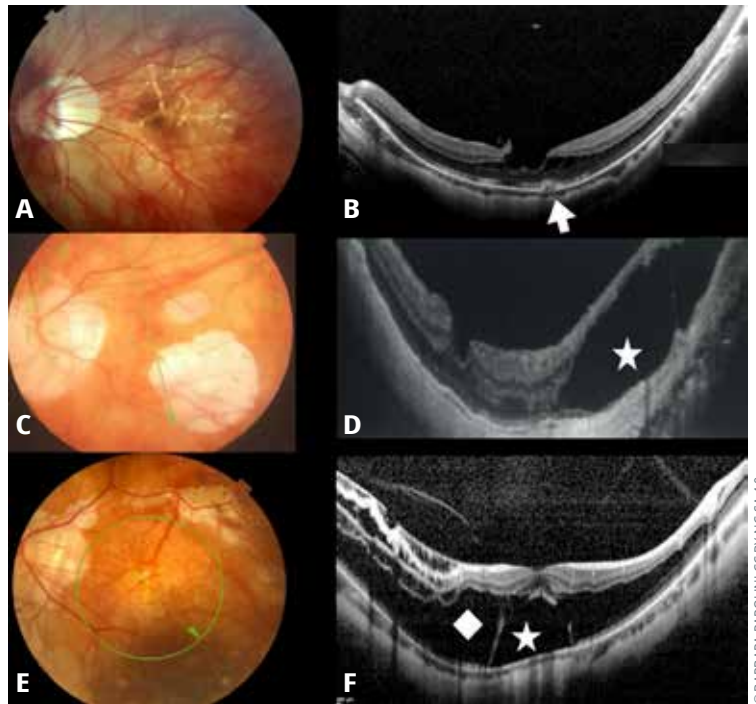
High myopia, defined as refractive error above 6 diopters (D) and/or axial length above 26.5mm (an eyeball longer than normal), affects a growing number of people worldwide, with the highest rates in urban Asian countries (5–9%).<sup>6</sup>

The progressive elongation of the myopic eye leads to three main consequences at the back of the eye: atrophy, neovascularisation, and tractional changes; collectively, these are known as **myopic maculopathy**.

- 1 Atrophy** indicates thinning of the choroid. The choroid, stretched by the elongation of the eye, breaks, creating lacquer cracks (see Figure 1 a and b), and then disappears (atrophy, see Figure 1, c and d). This complication is untreatable
- 2 Neovascularisation** is the formation of new vessels from the choroid to the retina (Figure 1b and Figure 2). This complication is treatable with intravitreal anti-VEGF injections.
- 3 Tractional changes** in the retina, (Figure 1e and f, and Figure 3) are known as myopic traction maculopathy (MTM); this may affect up to 30% of eyes with high myopia.

**Figure 1**

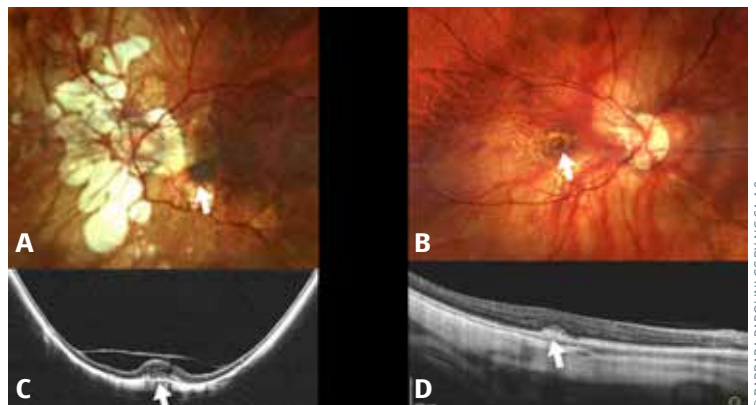
**A:** Colour fundus retinography showing the fundus of an eye with myopic maculopathy and lacquer cracks (yellowish lines at the posterior pole).  
**B:** OCT of the same eye in the macula showing the interruption in the choroid with a small choroidal neovascularization (arrow).  
**C:** Colour fundus retinography showing the fundus of an eye with myopic maculopathy and choroidal atrophy.  
**D:** OCT of the same eye displayed in C, with high myopia and areas of choroidal atrophy with serous retinal detachment (white star) correspondent to the atrophic area.  
**E:** Colour fundus retinography showing the fundus of an eye with myopic maculopathy and no apparent lesions.  
**F:** OCT showing myopic traction maculopathy (MTM) in the form of macular schisis (white diamond) and foveal detachment (white star).



© BARBARA PAROLINI CC BY-NC-SA 4.0

**Figure 2**

**A:** Color fundus retinography showing the fundus of an eye with myopic maculopathy and whitish atrophy in the peripapillary area. The arrow shows a choroidal neovascular membrane.  
**B:** Color fundus retinography showing the fundus of an eye with myopic maculopathy. There are no areas of atrophy. The choroidal vessels are visible in the typical tessellated fundus appearance. The arrow shows a choroidal neovascular membrane.  
**C:** OCT of the same eye displayed in A; the arrow indicates the choroidal neovascular membrane.  
**D:** OCT of the same eye displayed in A; the arrow indicates the choroidal neovascular membrane.

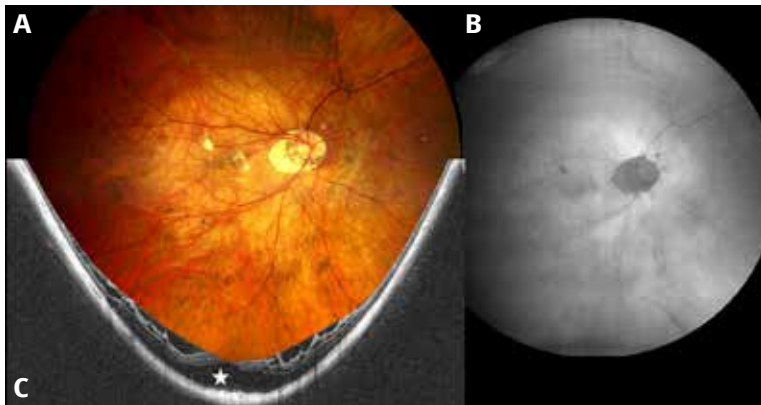


© BARBARA PAROLINI CC BY-NC-SA 4.0



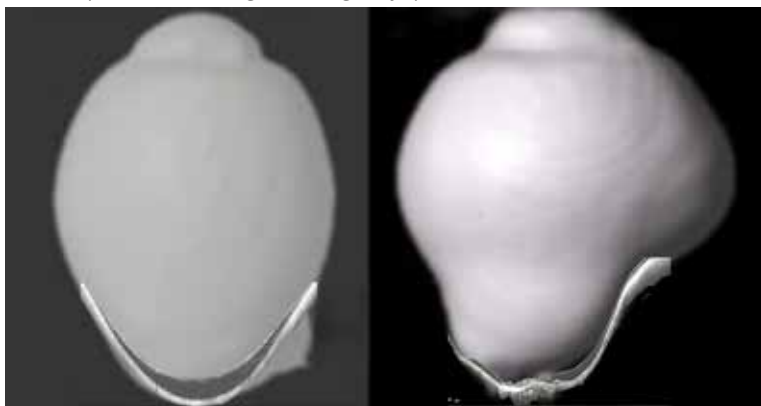
**Figure 3**

**A:** Colour fundus retinography showing the fundus of an eye with myopic maculopathy and laquer cracks (yellowish lines at the posterior pole) and small areas of whitish atrophy temporal to the papillae and along the superior arcade  
**B:** Autofluorescence of the same eye. The dark areas corresponds to atrophic zones  
**C:** Superimposed OCT of the same eye, showing myopic traction maculopathy in the form of macular schisis (white star).



© BARBARA PAROLINI CC BY-NC-SA 4.0

**Figure 4** 3D magnetic resonance imaging (MRI) of two eyes affected by posterior and lateral staphyloma, elongation of the eyewall and high myopia. The B-scan widefield OCT is superimposed on the posterior pole of the MRI images. The patient on the left has myopic traction maculopathy stage 2a, and the patient on the right has high myopia without traction.



© BARBARA PAROLINI CC BY-NC-SA 4.0

### Myopic traction maculopathy

Myopic traction maculopathy (MTM) is the term used to describe the different tractional effects on the macula due to the elongation of the eye as a result of high myopia. MTM may affect up to 30% of eyes with high myopia,<sup>2,3</sup> especially if a posterior staphyloma is present as an ectasia (or bulging) in the posterior eyewall. The ectasia of the posterior eyewall is visible with widefield OCT or magnetic resonance imaging (MRI), as shown in Figure 4.

MTM is considered a complex disease. But everything is complex only when it is not fully understood.

Until 2020, there was no comprehensive classification in the literature,<sup>4,5,7</sup> very limited information on pathogenesis and natural history, and no consensus on the complete terminology of the different types of myopic traction maculopathy, nor on treatment.

We analysed hundreds of OCT images of highly myopic eyes, affected by different stages of MTM, over a very long period and then published the MTM staging system (Figure 5). This divides MTM not in types but in stages<sup>8</sup>, to highlight the dynamic and continuously evolving nature of the disease. Next, we offered guidelines on the type and timing of management, customised for each stage.

### The stages of MTM

As the eye elongates and enlarges in progressive myopia, the macula might show signs of anteroposterior traction (traction perpendicular to the foveal plane) and tangential traction (traction at an angle to the foveal plane).

The four rows in the MTM staging system (Figure 5) represent the evolution of the disease in a direction perpendicular to the retina: from inner/outer schisis (splitting of the retinal layers) (stage 1) to predominantly outer schisis (stage 2) to schisis-detachment (stage 3) to complete macular detachment (stage 4). The three columns represent the evolution in a direction tangential to the retina and the fovea: from normal fovea (stage a) to

**Figure 5** Myopic traction maculopathy staging system.

		TANGENTIAL EVOLUTION							
		NORMAL FOVEAL PROPHYLE		TANGENTIAL EVOLUTION IN LMH		TANGENTIAL EVOLUTION IN FTMH			
	STAGE			STAGE			STAGE		
PERPENDICULAR EVOLUTION	Inner-Outer Macular Schisis	1a		1b		1c			
	AVERAGE BCVA	0,5		0,4		0,1			
	Time to next step	18 months		15 months		12 months			
	MANAGEMENT	Observation		PPV (if symptomatic)		PPV			
PERPENDICULAR EVOLUTION	Predominantly Outer Macular Schisis	2a		2b		2bO		2c	
	AVERAGE BCVA	0,3		0,2		0,1		0,1	
	Time to next step	12 months		6 months		1-3 months		1-3 months	
	MANAGEMENT	Observation		MB + Late PPV (if symptomatic)		MB + PPV			
PERPENDICULAR EVOLUTION	Macular Schisis-Detachment	3a		3aO		3b		3bO	
	AVERAGE BCVA	0,2		0,1		0,1		0,1	
	Time to next step	3 months		1-3 months		less than 1 months		less than 1 months	
	MANAGEMENT	MB		MB + Late PPV (if symptomatic)		MB + PPV			
PERPENDICULAR EVOLUTION	Macular Detachment	4a		4aO		4b		4bO	
	AVERAGE BCVA	0,1		0,1		0,1		0,1	
	Time to next step								
	MANAGEMENT	MB		MB + Late PPV (if symptomatic)		MB + PPV			

The PLUS sign "+" can be added to indicate epiretinal abnormalities and can be present in each stage

© BARBARA PAROLINI CC BY-NC-SA 4.0

inner lamellar macular hole (stage b) to full-thickness macular hole (stage c).

The outer lamellar macular hole is marked as O and might occur in stage 2, 3, or 4.

The presence of epiretinal abnormalities is marked as + (read as “plus”) and might occur in every stage.

The retina can evolve from stage 1 to stage 4 and from pattern a to c simultaneously or separately. The mean time taken to evolve from one stage to the next is marked in Figure 5, as well as the average visual acuity.

MTM stages might show a spontaneous improvement<sup>4</sup> However, we determined that, when the eyes are followed for a long time, MTM might start to evolve once again, even after spontaneous resolution.

### How we diagnose myopic traction maculopathy

Indirect ophthalmoscopy and biomicroscopy can identify pathologic myopia but not MTM. OCT is the key instrument to diagnose this disease.<sup>1,9</sup> In fact, the true description of MTM began with the advent of OCT.<sup>1</sup>

When OCT is not available, and the vision is good, we cannot exclude that MTM could be already present. However, usually in early stages, like stages 1a, 1b, 2a, 2b (Figure 5) vision is still in the range of 0,5–1,0 decimal, in the absence of macular atrophy.

When vision starts to decrease in the absence of atrophy, neovascularisation, and haemorrhages, we should suspect MTM in the form of stage 3, 4, or any stage c, even in the presence of a normal fundus appearance, as shown in Figure 1 e and f. These patients should be referred for OCT.

Ideally, all patients with high myopia should be referred for an OCT, if available, no matter what level of vision they have, in order to identify possible myopic maculopathy, classify the stage of myopic maculopathy (if present) and offer appropriate advice for future management.

### How we manage myopic traction maculopathy

Our studies show that, to obtain the best efficacy to safety ratio, patients in the early stages of myopic traction maculopathy, with intact fovea and good vision, should be observed, since progression is slow. For patients with more advanced disease, treatment is required:

- MTM, in the form of schisis and detachment of the macula, can be counteracted by placing a macular buckle which pushes the sclera towards the retina, solving the schisis and detachment.
- Lamellar or full thickness macular hole can be counteracted by pars plana vitrectomy (PPV) which creates a force pointing toward the centre of the fovea.

In summary, when vision is good, the patient should just be observed but with periodic OCT. In the presence of a macular detachment, a macular buckle should be applied.

If a macular hole is present, consider vitrectomy.

One great advantage of using a macular buckle to solve the schisis and detachment secondary to MTM is that it avoids the use of silicone oil, often proposed

when treating recurrent retinal detachments in MTM. Standard or heavy silicone oil in highly myopic eyes inevitably leads to secondary glaucoma.

### Macular buckle

The macular buckle is a device that shortens the eye. The surgical technique aims to counteract the pulling effect exerted on the retina by the elongation of the sclera. The buckling side of the device is placed behind the posterior pole, in order to push the sclera anteriorly.

Different models of macular buckle have been proposed.<sup>10</sup> Surgery may be performed under general or local anaesthesia. For local anaesthesia, we prefer sub-Tenon’s anaesthesia with a blunt cannula to avoid the potential risk of scleral perforation with a retrobulbar injection in highly myopic eyes. The surgical technique is shown in this video: <https://youtu.be/WdljLCHbYtE>

When following these guidelines, the prognosis of surgery is good, and the best corrected visual acuity improves with an average of 2 lines. It is particularly important to highlight this achievement, because, currently, high myopic eyes with myopic traction maculopathy are expected to improve only anatomically, not functionally, after surgery.<sup>11</sup>

### References

- 1 Pu Y, Chen J, et al. Global prevalence, trend and projection of myopia in children and adolescents from 1990 to 2050: a comprehensive systematic review and meta-analysis. *Br J Ophthalmol*. Published online September 24, 2024. doi:10.1136/bjo-2024-325427
- 2 Baba T, Ohno-Matsui K, Futagami S, et al. Prevalence and characteristics of foveal retinal detachment without macular hole in high myopia. *Am J Ophthalmol*. 2003;135(3):338-342. doi:10.1016/s0002-9394(02)01937-2
- 3 Benhamou N, Massin P, Haouchine B, Erginay A, Gaudric A. Macular retinoschisis in highly myopic eyes. *Am J Ophthalmol*. 2002;133(6):794-800. doi:10.1016/s0002-9394(02)01394-6
- 4 Shimada N, Tanaka Y, Tokoro T, Ohno-Matsui K. Natural course of myopic traction maculopathy and factors associated with progression or resolution. *Am J Ophthalmol*. 2013;156(5):948-957.e1. doi:10.1016/j.ajo.2013.06.031
- 5 Shimada N, Ohno-Matsui K, Yoshida T, Sugamoto Y, Tokoro T, Mochizuki M. Progression from macular retinoschisis to retinal detachment in highly myopic eyes is associated with outer lamellar hole formation. *Br J Ophthalmol*. 2008;92(6):762-764. doi:10.1136/bjo.2007.131359
- 6 Matsumura S, Ching-Yu C, Saw SM (2020). Global Epidemiology of Myopia. In: Ang M, Wong T (eds) *Updates on Myopia*. Springer, Singapore. [https://doi.org/10.1007/978-981-13-8491-2\\_2](https://doi.org/10.1007/978-981-13-8491-2_2)
- 7 Ruiz-Medrano J, Montero JA, Flores-Moreno I, Arias L, García-Layana A, Ruiz-Moreno JM. Myopic maculopathy: Current status and proposal for a new classification and grading system (ATN). *Prog Retin Eye Res*. 2019;69:80-115. doi:10.1016/j.preteyeres.2018.10.005
- 8 Parolini B, Palmieri M, Finzi A, et al. The new Myopic Traction Maculopathy Staging System. *Eur J Ophthalmol*. 2021;31(3):1299-1312. doi:10.1177/1120672120930590
- 9 Panozzo G, Mercanti A. Vitrectomy for myopic traction maculopathy. *Arch Ophthalmol*. 2007;125(6):767-772. doi:10.1001/archophth.125.6.767
- 10 Parolini B, Frisina R, Pinackatt S, Mete M. A new L-shaped design of macular buckle to support a posterior staphyloma in high myopia. *Retina*. 2013;33(7):1466-1470. doi:10.1097/IAE.0b013e31828e69ea
- 11 Parolini B, Palmieri M, Finzi A, Frisina R. Proposal for the management of myopic traction maculopathy based on the new MTM staging system. *Eur J Ophthalmol*. 2021;31(6):3265-3276. doi:10.1177/1120672120980943
- 12 Takai Y, Tanito M, Sugihara K, Kodama T, Ohira A. Temporal inverted internal limiting membrane flap technique for a macular hole patient unable to maintain postoperative prone positioning. *Retin Cases Brief Rep*. 2016;10(4):323-326. doi:10.1097/ICB.0000000000000258



**Miriam Cano**  
Head of  
Ophthalmology:  
Catholic University  
of Asunción School  
of Medicine,  
Asunción, Paraguay.



**Mangala Dhanapala**  
Consultant  
Vitreoretinal  
Surgeon: Retina  
Research Unit,  
National Eye  
Colombo, Sri Lanka.



**Mengtian Kang**  
Ophthalmologist:  
Tongren Hospital,  
Beijing, China.



**Mapa Prabhath Piyasena**  
Deputy Director:  
Vision and Eye  
Research Institute,  
Faculty of Health,  
Medicine and Social  
Care, Anglia Ruskin  
University, UK.



**Rajiv Raman**  
Professor: Medical  
Research Foundation,  
Sankara Nethralaya  
& Indian Institute of  
Technology, Madras,  
Chennai, India.



**David Yorston**  
Consultant  
Ophthalmologist,  
Tennent Institute of  
Ophthalmology,  
Gartnavel Hospital,  
Glasgow, Scotland.

# Biosimilars for anti-VEGF treatment of macular diseases: country and region reports

Biosimilars can improve patients' access to anti-VEGF treatment for macular diseases, but only if they are approved for local use and are readily available.

A major barrier to the treatment of macular diseases is the cost of anti-VEGF drugs. As the patents on these drugs expire, lower cost biosimilar drugs have become available. According to the World Health Organization, a biosimilar is a bio-therapeutic product which is similar in terms of quality, safety and efficacy to an already licensed (or reference) bio-therapeutic product.<sup>1</sup>

They are similar, not equal; their active ingredients are not identical to those of the reference product. The adoption of a biosimilar varies between countries due to factors such as regulatory approval, market acceptance, and health care policies.<sup>1-2</sup>

The following short reports from Latin America, Sri Lanka, and China give an insight into how the introduction of biosimilars has affected practice in these regions.

There are some common themes.

- 1 The biosimilars appear to be safe and effective, and no concerns were raised about the quality of locally produced biosimilar agents.
- 2 The price of biosimilars remains high, at 30–80% of the cost of the original product. This is a considerable saving, but it is still too much for many patients. We should remember that the cost of anti-VEGF treatment is not just the price of the drug; it includes lost wages every month, and travel to and from the injection centre.
- 3 Bevacizumab, a reference drug, remains the lowest cost treatment in many countries: by using one vial for multiple patients, the cost can be as low as US\$10 per injection. However, a shared vial is not without risk, and large numbers of injections are needed to achieve this level of cost-effectiveness.

This is a rapidly developing field. At one time, intraocular lenses (IOLs) were too expensive for widespread use in low- and middle-income countries. However, locally manufactured IOLs are now cheaper than spectacles and their availability has transformed cataract surgery. We can hope that we will see similar developments with biosimilar anti-VEGF agents.

## China

An aging population, and the rising prevalence of diabetes, makes the need for anti-VEGF treatment of macular diseases particularly acute in China. Clinical guidelines recommend anti-VEGF drugs as the first-line treatment of age-related macular degeneration (AMD) and diabetic macular oedema (DMO). Lucentis (ranibizumab), Eylea (aflibercept), and Lumitin (conbercept) are the main anti-VEGF drugs in the Chinese market, and the price of

one injection are Chinese yuan (CNY) 3,674 (US\$502), CNY 4,150 (US\$567), CNY 3,452 (US\$470), respectively.

Zhuocuming (by Qilu Pharmaceutical Co), a biosimilar of aflibercept intraocular injection solution, was officially approved by the National Medical Products Administration (NMPA) for the treatment of adult patients with AMD and DMO. Zhuocuming is priced at CNY 2,970 (US\$406) per injection. The phase 3 clinical trials are underway.

## Latin America

In Latin America, patients have access to all the anti-VEGF drugs on the market. However, many fail to complete their course of treatment due to the high cost. Latin American countries Argentina, Brazil and Mexico are active members of the Pharmaceutical Inspection Co-operation Scheme ([picscheme.org](http://picscheme.org)), which makes it possible for them to use biosimilars.<sup>2</sup> Argentina and Brazil are the countries with the most biosimilars approved (more than 10 each). However, biosimilars are not often used in the region, because a single injection of a biosimilar could be over US\$1,000 just for the medication,<sup>3</sup> compared to the cost of US\$50–70 for an intravitreal injection of bevacizumab.

As long as bevacizumab is cheaper than any biosimilar, there is no reason to use the latter. There is also currently more trust in bevacizumab thanks to the 2011 CATT Study,<sup>4</sup> funded by the National Eye Institute in the USA, and the study published by the Pan-American Collaborative Retina Study Group in 2016.<sup>5</sup>

## Sri Lanka

Most of the anti-VEGF drugs used worldwide are available in Sri Lanka. The commonly used ones are bevacizumab (Avastin), ranibizumab (Lucentis), aflibercept (Eylea) and faricimab (Vabysmo). Patizra, the ranibizumab preparation provided for low-and-middle-income countries by Novartis Indonesia, is also available in Sri Lanka.

Biosimilar bevacizumab preparations available in Sri Lanka are Avegra (by BIOCAD) and Abermy (by Biocon Ltd). The biosimilar for aflibercept that is locally available is Zaltrap (by Regeneron).

In clinical practice, one vial of bevacizumab is shared among 30 to 40 patients, hence the cost for an injection in the public sector is around Sri Lankan Rupee (LKR) 4,000 (US\$13) per patient; this is given to patients free of charge. In the private sector, the cost per bevacizumab injection ranges from LKR 16,000 to 35,000 (US\$54–118); the cost of Patizra injections ranges from LKR 90,000 to LKR 125,000 (US\$303–420), and



the cost per Vabysmo injection ranges from LKR 300,000 to LKR 325,000 (US\$1,010–1,094).

Biosimilar anti-VEGF agents in Sri Lanka are little cheaper than the original product, but there are few designated local suppliers, which explains why these biosimilars are not more popular amongst retina specialists.

See article on p22 for more on biosimilars in Sri Lanka.

## India

India approved the world's first ranibizumab biosimilar, Razumab (by Intas Pharmaceuticals), in 2015. This biosimilar is approved for all conditions in which ranibizumab might be used, including neovascular (wet) AMD, DMO, retinal vein occlusions, and retinopathy of prematurity. Other notable biosimilars available in India include Ranibizumab-nuna (Byooviz), by Samsung Bioepis and Biogen, and several other candidates such as Ranizurel (by Reliance Life Sciences) and Ranieyes (by Lupin Limited), each having proven their efficacy and safety in clinical trials comparable to the reference drugs.<sup>6,7</sup>

Biosimilars are significantly cheaper than their branded counterparts, typically costing 35–50% less. This price reduction is due to the lower research and development costs associated with biosimilars compared to originator biologics.

Initial concerns about intraocular inflammation linked to early batches of Razumab were addressed by adjusting manufacturing processes, setting a precedent for robust quality controls in biosimilar production.<sup>8</sup>

Other drugs are in development. Several aflibercept biosimilars are poised to enter the market once patent protections expire. India's ability to develop and manufacture low cost biosimilars is expected to improve global access to treatments for retinal diseases.<sup>9,10</sup>

## References

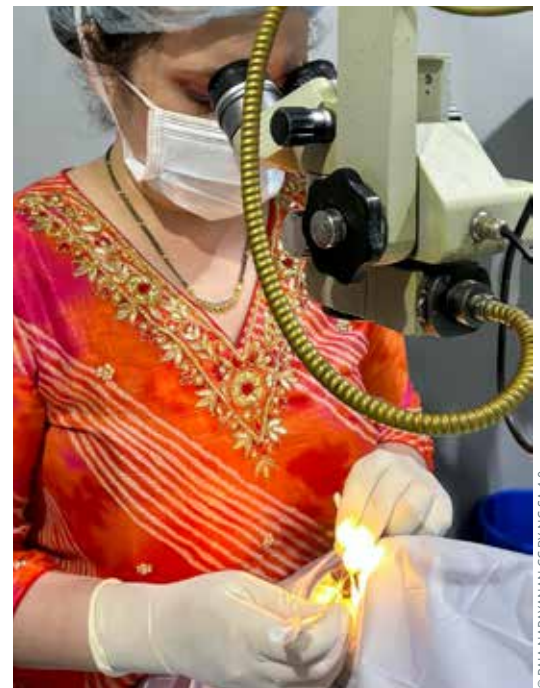- 1 Karp P, Gatto M, Batto MV, et al. Biosimilar monoclonal antibodies in Latin America. doi: 10.5772/intechopen.101227
- 2 Overview of monoclonal antibody biosimilars in Latin America. Accessed 22 January 2025. [bit.ly/4gb0eyt](https://bit.ly/4gb0eyt)
- 3 <https://www.aao.org/eyenet/article/expensive-drugs>. Accessed 10 January 2025.
- 4 The CATT Research Group. Ranibizumab and bevacizumab for neovascular age-related macular degeneration. *N Engl J Med* 2011; 364:1897-908. Epub 2011 Apr 28. PMC3157322.
- 5 Arevalo JF, Lasave AF, Wu L, Acon D, Farah ME, Gallego-Pinazo R, et al. Intravitreal bevacizumab for diabetic macular oedema: 5-year results of the Pan-American Collaborative Retina Study group. *Br J Ophthalmol*. 2016; 100:1605–1610. doi: 10.1136/bjophthalmol-2015-307950.
- 6 Verma L, Thulasidas M, Purohit A, Gupta A, Narula R, Talwar D. Clinical efficacy and safety of Razumab® (CESAR) study: Our experience with the world's first biosimilar Ranibizumab. *Indian J Ophthalmol*. 2021;69(2):347-351. doi:10.4103/ijo.ijo\_2516\_20
- 7 Sharma S, Sharma T, Prasad S, Gopalakrishnan M, Chaturvedi A. Treatment Landscape of Macular Disorders in Indian Patients with the Advent of Razumab™ (World's First Biosimilar Ranibizumab): A Comprehensive Review. *Ophthalmol Ther*. 2021;10(3):431-443. doi:10.1007/s40123-021-00362-1
- 8 Sharma S, Gupta V, Maiti A, et al. Safety and efficacy of Razumab™ (world's first biosimilar ranibizumab) in wet age-related macular degeneration: a post-marketing, prospective ASSET study. *Int J Retina Vitreous*. 2021;7(1):24. doi:10.1186/s40942-021-00293-w.
- 9 Sharma A, Kumar N, Parachuri N, Loewenstein A, Bandello F, Kuppermann BD. Preparing for the next decade of anti-VEGF biosimilars for retinal diseases: a focus on South Asia. *Expert Opin Biol Ther*. 2023;23(8):689-692. doi:10.1080/14712598.2023.2239706
- 10 Hariprasad SM, Gale RP, Weng CY, Ebberts HC, Rezk MF, Tadayoni R. An Introduction to Biosimilars for the Treatment of Retinal Diseases: A Narrative Review. *Ophthalmol Ther*. 2022;11(3):959-982. doi:10.1007/s40123-022-00488-w

# Working with patients affected by macular eye conditions

Age-related macular degeneration (AMD) and diabetic macular oedema (DMO) are serious conditions, often leading to loss of vision. AMD and DMO affect the central vision, making it hard to read, recognise faces, and see objects clearly. Anti-VEGF drugs can help to stabilise both conditions and slow down vision loss.



**Raja Narayanan**  
Director: Anant Bajaj Retina Institute, LV Prasad Eye Institute, Hyderabad, India.



Giving an anti-VEGF injection. INDIA

## References

- 1 Wong WL, Su X, Li X, Cheung CMG, Klein R, Cheng CY, et al. Global prevalence of age-related macular degeneration and disease burden projection for 2020 and 2040: a systematic review and meta-analysis. *Lancet Glob Health*. 2014;2(2):e106-16.
- 2 Magliano DJ, Boyko EJ. IDF Diabetes Atlas, 10th edition. Brussels: International Diabetes Federation, 2021. Available from: <https://tinyurl.com/252kyedz>
- 3 Macular degeneration treatment market – global growth, trends, Covid-19 impact, and forecasts 2021–2026. Available from: <https://tinyurl.com/zh6vv2n3>

The prevalence of AMD is estimated to be 170 million globally, with 90% of patients affected by dry AMD.<sup>1</sup> It is estimated that the number of people with diabetes mellitus (DM) worldwide will increase by 46%, from 537 million in 2021 to 783 million in 2045.<sup>2</sup>

The most common treatment for wet AMD and DMO is anti-vascular endothelial growth factor (anti-VEGF) injections, given into the eye. Intravitreal injections of anti-VEGF drugs can help to stabilise the disease, but the treatment requires frequent visits to the doctor and repeated injections, over many years. This can be challenging and stressful for patients and their families.

Financial costs, anxiety, and access to care are major barriers that can prevent patients from sticking to their treatment plan.<sup>3</sup> Undertreatment is the most common cause for poor visual outcomes.

Studies from various countries show that continued treatment over many years is required in AMD and DMO, and that most patients regain some vision over time (an average of 10 letters). While visual improvement may be limited, the treatment prevents the severe vision loss that would otherwise be inevitable.

### Understanding patients' concerns

To improve adherence to treatment, it is vital to understand patients' concerns beyond just the cost. Factors like anxiety, lack of information, and family burden can prevent adherence to treatment. Improving patients' understanding of the condition, treatment routine, and the possible treatment outcomes, can make them more likely to continue with their treatment.

A common concern among patients receiving an injection for the first time is that it will be very painful. I explain to them that we perform the injection after instilling anaesthetic eye drops into the eye, and there will be a pricking sensation rather than pain. Patients who undergo repeat injections are usually not anxious about the pain.

A bigger concern among patients is the visual outcome after multiple injections. Even though patients are counselled about the possibility of only limited improvement with this treatment, their expectations can be high. It is important to talk to family members as well, and keep their expectations reasonable. Explain to them that the main goal of the treatment is to maintain vision, and their eyesight is likely to deteriorate if they do not follow the schedule of injections as prescribed.

Most patients with DMO and AMD will experience some visual impairment and will benefit from referral to low vision and rehabilitation services.

# Availability and affordability of anti-VEGF biosimilars for the treatment of age-related macular degeneration and diabetic macular oedema in Sri Lanka

In Sri Lanka, anti-VEGF biosimilars are available free of cost in the public eye health care system for treatment of macular diseases.



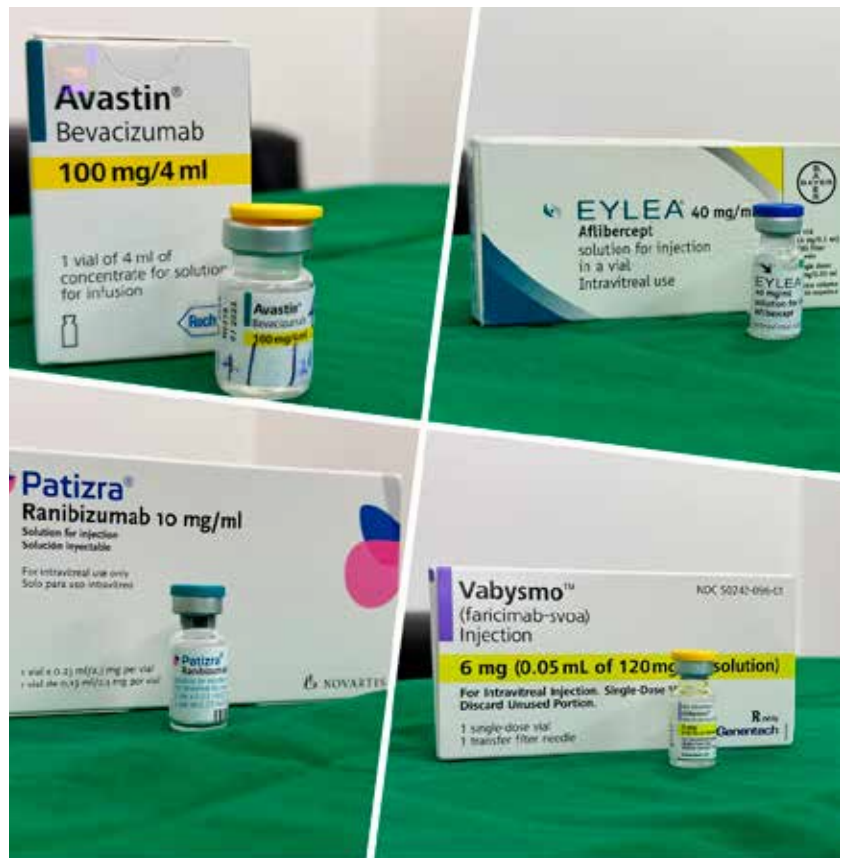**Mapa Prabhath Piyasena**

Deputy Director:  
Vision and Eye  
Research Institute,  
Faculty of Health,  
Medicine and  
Social Care, Anglia  
Ruskin University,  
UK.



**Mangala Dhanapala**

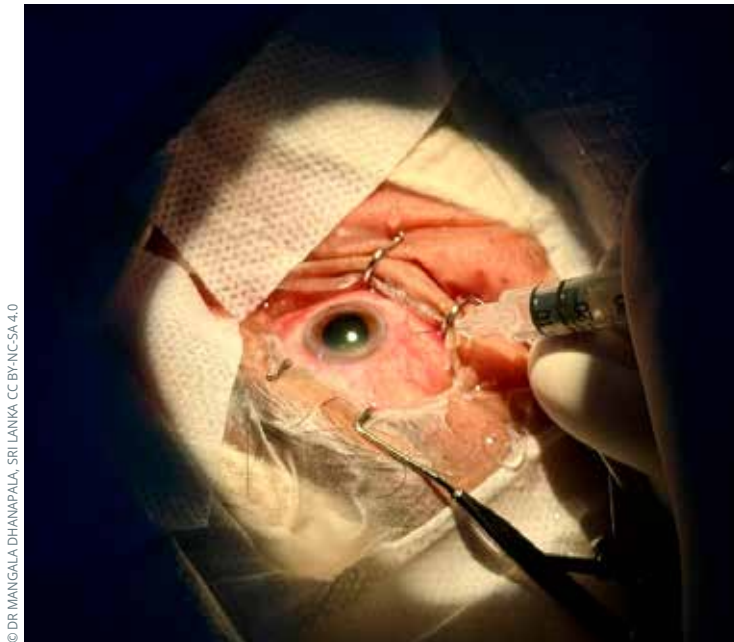
Consultant  
Vitreo-Retinal  
Surgeon: Retina  
Research Unit,  
National Eye  
Hospital, Colombo,  
Sri Lanka.



**Figure 1** Vials of anti-VEGF injections available in Sri Lanka.

With the rapidly ageing population and increasing prevalence of diabetes mellitus (the latest population-based survey reports the age-standardised prevalence of diabetes as 21.8%<sup>1</sup>), the most common macular diseases among adults in Sri Lanka are diabetic macular oedema and age-related macular degeneration.

The eye care in Sri Lanka is provided by the public sector, private sector, and non-governmental organisations ('third sector'). The public sector provides all aspects of eye care services, including anti-vascular endothelial growth factor (anti-VEGF) injections, free of charge to the citizens of Sri Lanka. The medical supplies division of the ministry of health in Sri Lanka provides the required number of anti-VEGF injections island-wide to those tertiary and secondary level health care institutions where a specialist general ophthalmologist or a specialist vitreo-retinal surgeon is available. In Sri Lanka, many general ophthalmologists perform retinal procedures; these ophthalmologists can therefore administer anti-VEGF injections to patients. Intravitreal injections are administered in the main operating theatres under strict sterile conditions.



© DR MANGALA DHANAPALA, SRI LANKA CC BY-NC-SA 4.0

**Figure 2** An image of treating a patient with an Intra-vitreous injection in an operating theatre in Sri Lanka.

Intravitreal anti-VEGF injections are an effective main mode of treatment for macular diseases globally.<sup>2,3</sup> Most of the anti-VEGF biosimilars used worldwide are also available in Sri Lanka. The commonly used ones are bevacizumab (Avastin), ranibizumab (Lucentis), aflibercept (Eyelea), and faricimab (Vabysmo). Biosimilar bevacizumab preparations available in Sri Lanka are Avegra (by Biocad) and Abevmy (by Biocon Ltd). The biosimilar aflibercept that is available is Zaltrap (by Regeneron). Original ranibizumab is available, in addition to Patizra, which is the ranibizumab preparation made available for low- and middle-income countries by Novartis Indonesia (Figure 1).

Public sector hospitals in Colombo, which cover the Greater Colombo area, carry out around 2,000 anti-VEGF injections per month, while the private sector hospitals catering for this area also provide roughly the same number (approximately 24,000 injection doses per year in a district with 500,000 people with diabetes). Out of these, around 90% of the injections are Avastin, with the remaining 10% comprising Patizra, Eyelea, and Vabysmo. In clinical practice one Avastin vial is shared among 30 to 40 patients, hence the cost of an injection in the public sector is around LKR 4,000 (roughly US \$13.50) per patient. It is given free of charge to the patient. In the private sector, the cost per Avastin injection ranges from LKR 16,000 to LKR 35,000 (roughly US \$53 to \$117); per Patizra injection, from LKR 90,000 to LKR 125,000 (roughly US \$300 to \$417); and per Vabysmo injection, from LKR 300,000 to LKR

325,000 (roughly US \$1,000 to \$1,084). The problems with regard to the use of biosimilar anti-VEGF agents in Sri Lanka pertain to the cost of the products (the prices are very close to that of the original product) and the lack of designated local suppliers for them. These are the probable reasons why these products are not very popular amongst retina specialists.

Patients can choose the private sector for anti-VEGF care, in which case the hospital charges and cost of medicines or procedures have to be paid out of pocket. If a patient cannot afford anti-VEGF care in the private sector, they will be referred to the nearest secondary level or tertiary level public sector specialist eye unit, without the need for a referral letter from a general practitioner, as is the case in some high-income countries. This has improved access to anti-VEGF injections.

The issue of lack of adherence to prescribed anti-VEGF treatment in Sri Lanka has not been scientifically studied. Anecdotal evidence shows that most of the barriers are associated with a lack of awareness of the importance of treatment, difficulties in managing travel logistics, not having someone to accompany the patient to appointments, or fear and anxiety about injections.

The recommended treatment of a monthly spaced loading dose, followed by a treat and extend or PRN (pro re nata) regimen, is not strictly followed by the patients, especially those from low socio-economic backgrounds, because losing a day's wages (to receive treatment) is a significant burden on patients and their families.

## Two common approaches after the monthly loading dose

**1. Treat and extend.** If the macula stays dry, the time between injections is gradually increased by two weeks, up to 12 weeks. However, every visit includes an injection to prevent swelling from returning.

**2. Pro re nata (PRN) or 'as needed'.** Patients are checked monthly, and injections are given only if swelling (oedema) reappears.

For some patients, if the swelling doesn't improve after the initial three doses, doctors may recommend three more monthly injections.

These methods help tailor the treatment to the patient's needs while balancing effectiveness and the number of visits required. However, many patients, especially those on low incomes, find it hard to follow these schedules due to the financial burden of missing work for frequent visits.

## References

- 1 Rannan-Eliya RP, Wijemunige N, Perera P, Kapuge Y, Gunawardana, N, Sigeru, C, et al. Prevalence of diabetes and pre-diabetes in Sri Lanka: a new global hotspot – estimates from the Sri Lanka Health and Ageing Survey 2018/2019. *BMJ Open Diabetes Res Care.* 2023;11(1).
- 2 Virgili G, Parravano M, Evans JR, Gordon I, Lucenteforte E. Anti-vascular endothelial growth factor for diabetic macular oedema: a network meta-analysis. *Cochrane Database Syst Rev.* 2018;10(10).
- 3 Solomon SD, Lindsley K, Vedula SS, Krzystalik MG, Hawkins BS. Anti-vascular endothelial growth factor for neovascular age-related macular degeneration. *Cochrane Database Syst Rev.* 2019;3(3).



# Key community eye health messages

## 1. Understanding Macular Health

- The macula is the central part of the retina responsible for sharp vision, reading, and recognising faces. Any damage to the macula can lead to significant vision problems.
- Macular diseases like diabetic macular oedema (DMO), age-related macular degeneration (AMD), and myopic maculopathy are increasing worldwide due to ageing, diabetes, and high myopia.
- Early detection is crucial. Encourage regular eye check-ups, especially for people with diabetes and those over 60 years of age.

## 2. Preventing and Managing Macular Diseases

- Diabetes can damage the macula: People with diabetes must control their blood sugar, blood pressure, and cholesterol to prevent diabetic macular oedema.
- Lifestyle choices matter: Smoking, poor diet, and obesity increase the risk of macular diseases.
- Myopia can lead to macular damage: People with high myopia should have regular eye exams to monitor for myopic maculopathy and related complications.

## 3. Supporting Patients with Macular Conditions

- Recognising symptoms: Blurred or distorted central vision, difficulty reading, trouble recognising faces, and dark or blank spots in vision are signs of macular diseases.
- Anti-VEGF treatment can stop vision loss: For AMD and DMO, anti-VEGF injections are effective. Refer patients early for specialist care.
- Low vision support is essential: Patients with macular diseases may not go completely blind but need low vision aids, rehabilitation, and support to maintain independence.
- Community awareness is key: Organize screenings, health talks, and awareness campaigns to educate people about macular health and early diagnosis.

